

JOURNAL *of the*

MASSACHUSETTS DENTAL SOCIETY

Fall 2009

Using Lasers to Treat
Oral Manifestations
of Behçet's Syndrome

SIMPLE TRUTHS

WE WRITE THESE WORDS AS OUR GOVERNMENT AND CITIZENS BATTLE (SOMETIMES LITERALLY) over health care reform and as our state and nation have lost two Kennedy siblings, one the longtime “Lion of the Senate” and the other the founder of the Special Olympics Program.

Since 1968, the Special Olympics has raised the quality of life and self-esteem of countless people with special needs. Eunice Kennedy Shriver also understood the benefits of good oral health. She paved the way for dentistry to be a part of the Special Olympics competitions, opening doors to dental care to a truly underserved population, many of whom had never received even rudimentary dental evaluation. One of our own members, Dr. Steve Perlman, spearheaded this effort, which has grown to worldwide dimensions and brought higher respect to all of us as a profession.

Senator Edward M. Kennedy was a champion for public health causes. Ironically, while it often seemed popular among our peers to oppose anything he said, far more often than not he fought for many of the same causes we, as a profession, also sought. Ted Kennedy and Eunice Kennedy Shriver were people of privilege who used their inherited advantages and natural talents to do what they could to improve the world around them. Whether or not we agree with all that they did, it cannot be argued that they left the world a better place.

However, this is not meant to be a political treatise. Your editors recently lost a mutual friend who was also one of our colleagues. He, like all of us, strived to provide the best care that he could to the people who entrusted their oral health to him. He was a consummate clinician. He, like any of us, was not perfect. He lived with the day-to-day challenges we all face. His passing, all too sudden, all too soon, is a reminder that we, as professionals, as family members, as citizens, and as friends, do not have infinite time to accomplish all we hope to do in any of the facets of our lives.

By the time you read this, national health care reform may be an accomplishment, a quagmire, or a total failure. No matter where we stand in the progress of any of the multitude of public efforts to improve the health of our society, some simple truths remain.

Our time allotment to accomplish our goals is unknown.

We are given the expectations of those who come to us for care to do our best to restore and maintain health.

Whether we are a senator, a philanthropist, or a dentist, we are obliged to try to leave the world a better place.

Our friend did.

Let's hope that in the very distant future, the same is said for each of us.

Our lives, individually and collectively, are precious. What really matters is how we live the life each of us is given, and what we do to leave the world a better place. ■



David B. Becker

Arthur I. Schwartz

JOURNAL OF THE
MASSACHUSETTS DENTAL
SOCIETY

EDITOR

David B. Becker, DMD

ASSISTANT EDITOR

Arthur I. Schwartz, DMD

EDITOR EMERITUS

Norman Becker, DDS

MANAGING EDITOR OF
PUBLICATIONS AND WEB SITE
Melissa Carman

MANAGER, GRAPHIC DESIGN
Jeanne M. Burdette

GRAPHIC DESIGNER
Shelley Padgett

Editorial Board

Bruce Donoff, DMD, MD

Robert Faiella, DMD

Russell Giordano, DMD

Shepard Goldstein, DMD

Stephen McKenna, DMD

John McManama, DDS

Noshir Mehta, DMD

Charles Millstein, DMD

Philip Millstein, DMD

Maria Papageorge, DMD

Michael Sheff, DMD

Steven Tonelli, DMD

Copyright © 2009 Massachusetts Dental Society
issn: 0025-4800

The JOURNAL OF THE MASSACHUSETTS DENTAL SOCIETY [usps 284-680] is owned and published quarterly by the Massachusetts Dental Society, Two Willow Street, Suite 200, Southborough, MA 01745-1027. Subscription for nonmembers is \$15 a year in the United States. Periodicals postage paid at Southborough, MA, and additional mailing offices.

Postmaster: Send address changes to: Journal of the Massachusetts Dental Society, Two Willow Street, Suite 200, Southborough, MA 01745.

Contributions: Contact the Communications Department, or visit www.massdental.org for author's guidelines.

Display ad closing dates: February 1, May 1, August 1, November 1. For more information, contact Rachel Marks, Exhibits Coordinator, at (508) 480-9797, ext. 259, or email rmarks@massdental.org.

Member Publication
American Association
of Dental Editors



Securities offered through NEXT Financial Group, Inc., Member FINRA/SIPC. EDFS is not an affiliate of NEXT Financial Group, Inc. EDFS/Eastern Dental Financial Services, LLC, 200 Friberg Parkway, Suite 2002, Westborough, MA 01581. Phone: (800) 898-3342. Fax: (508) 870-2897. Copyright 2009 Forefield Inc. All Rights Reserved.

INVESTING IN A LOW-INTEREST-RATE ENVIRONMENT

LOW INTEREST RATES CREATE A DILEMMA: DO YOU ACCEPT A LOW RETURN because you feel you must protect your principal, or do you take on greater investment risk in order to try for a higher return? In balancing these two concerns, there are some factors to consider.

Laddering Your CDs

When yields on Treasury bonds began dropping last year, many investors were attracted to certificates of deposit (CDs) offered by banks that needed to attract capital. However, interest rates won't stay low forever, and at some point you may want access to your money before a CD matures. One way to achieve higher rates while retaining flexibility to adjust your strategy over time is to ladder CDs. Laddering involves investing in CDs with varying maturity dates. As the shorter-term CDs mature, you can reinvest in one with a longer term and higher rate. Over time, laddering can give you both the higher rates typically offered by longer-term CDs and the ability to adjust as interest rates change.

For example, Susan wants to invest \$60,000 in CDs. She puts \$20,000 in a six-month CD that pays 2.6 percent, another \$20,000 in a three-year CD that pays 3 percent, and the final \$20,000 in a five-year CD that pays 3.5 percent. When the six-month CD matures, she reinvests that money in another five-year CD. When her two-year CD matures, she reinvests it in still another five-year CD. At that point, funds from a maturing CD will be available roughly every other year, but will earn the higher five-year rate. If rates are lower when a CD matures, she has the option of investing elsewhere. (This is a hypothetical example and doesn't represent the results of any specific investment.)

Pay Attention to Expenses

Low returns magnify the impact of high investing expenses. Let's say a mutual fund has an expense ratio of 1.00, meaning that 1 percent of its net asset value each year is used to pay operating expenses such as management and marketing fees. That 1 percent represents a bigger relative bite out of your return when the fund is earning 3 percent than it does if it's earning 10 percent. At the higher number, you're losing only about 10 percent of your return; at 3 percent, almost a third of your return goes to expenses. Before investing in a mutual fund, carefully consider its fees and expenses as well as its investment objective and risks, which can be found in the prospectus available from the fund.

Read the prospectus carefully before investing. If you prefer individual stocks, keep an eye on trading costs.

Think About Your Real Return

Low interest rates may not be quite as problematic as they seem. Even if you're earning a low interest rate, your real return might not suffer too much if inflation is also low. Real return represents what your money earns once the impact of inflation is taken into account. With an annual inflation rate of 0.1 percent—the December 2008 Consumer Price Index figure—a bond that pays 3 percent would produce the same real return as a bond that pays 5 percent when annual inflation is running at 2.1 percent.

Compare Interest Rate and Yield Spreads

When market instability drove many investors to the safety of Treasury bonds, their prices rose and yields fell. As a result, the spreads between Treasury yields and those of corporates and municipals have been relatively high over the last year because non-Treasury bonds have to offer higher yields to compensate for investors' anxiety about the safety of their principal and possibility of default.

Consider Small Changes

You may not need to remake your portfolio completely to seek a higher return. For example, if you're in Treasury bonds, you could move part of that money to municipal bonds, which may involve greater risk of default but whose net returns are boosted by their exemption from federal income tax. Or you could shift a portion of your stock allocation to dividend-oriented stocks and exchange-traded funds (ETFs), or preferred stock.

Look for Buying or Selling Opportunities

Interest rates also can be used to help evaluate equities. Some analysts like to determine the relative value of the stock market using the so-called Fed market valuation model. (Though not officially endorsed by the Federal Reserve Board, the method evolved based on a 1997 Fed report.) The model compares the earnings yield on the S&P 500 to the 10-year Treasury bond's yield. If the S&P's yield is higher than the T-bond's, the model considers the market undervalued relative to bonds. If the Treasury yield is higher, the market is overvalued. However, this is only one of many valuation models and shouldn't be the sole factor in your decision. ■



GEORGE GONSER

Mr. Gonser is the former chief executive officer of MDSIS.

NEED 150 MILLION REASONS TO GET IDENTITY THEFT INSURANCE?

I OPENED UP THE PAPER THE OTHER DAY TO READ ABOUT A WORLDWIDE security breach that resulted in 150 million credit card numbers being “hacked” and their information released worldwide. “The scheme is believed to constitute the largest hacking and identity theft case ever prosecuted by the U.S. Department of Justice,” the article said. So are you protected?

Let’s start with the definition of identity theft. Identity theft is a term describing when an impostor gives another person’s name and/or personal information—such as a driver’s license, credit card, date of birth, or Social Security number—to secure a job, access bank accounts, buy a car, receive medical care, or acquire other types of goods and services.

To most of us, identity theft is what happens to other people. But in reality, one in six Americans will be a victim of identity theft this year. More than 10 million people have had some type of identity theft crime committed against them. Victims of identity theft spend an average of \$1,500 in out-of-pocket expenses and 175 hours in their efforts to resolve the many problems caused by identity thieves.

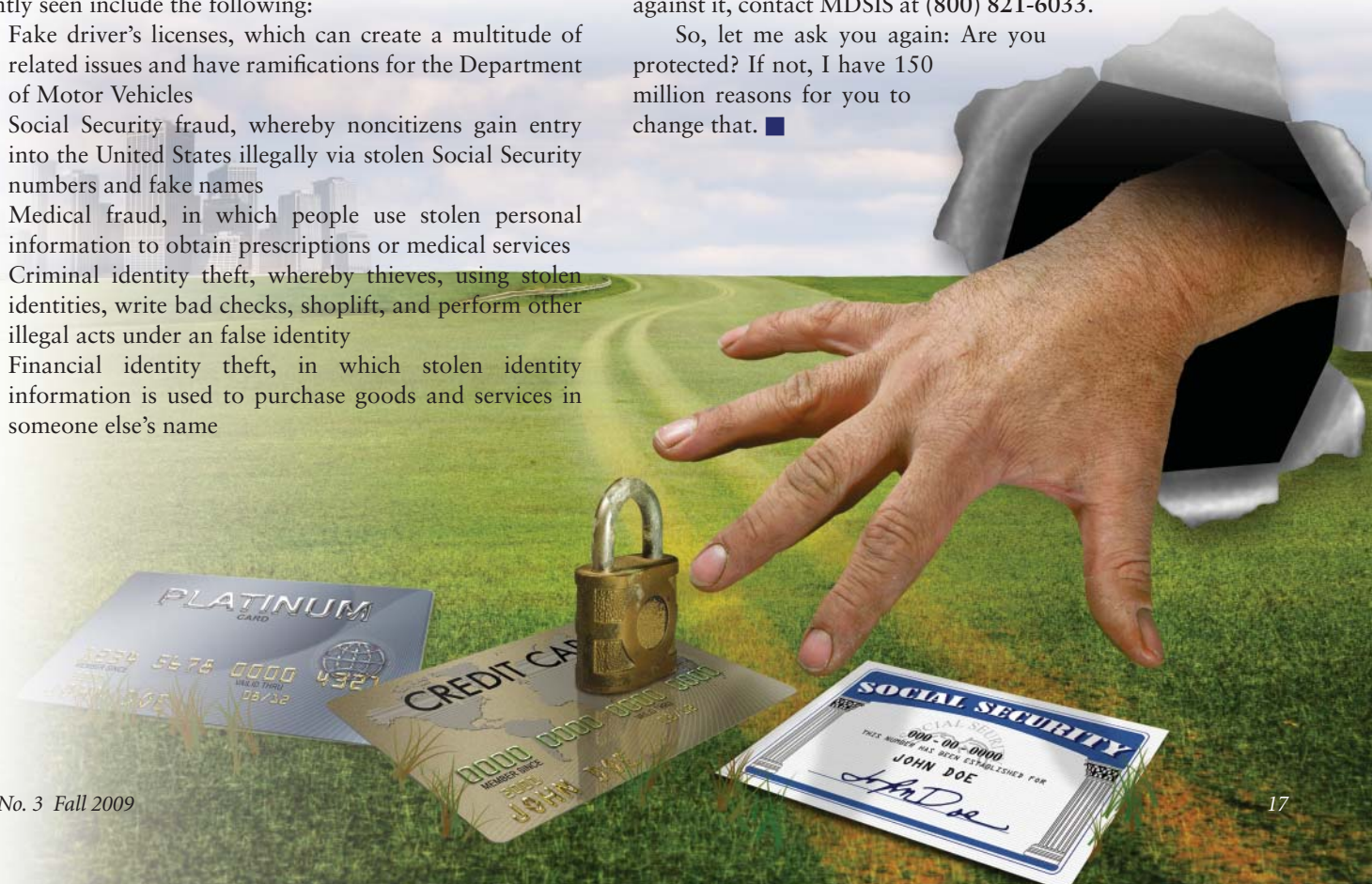While there are many types of identity theft, the five most frequently seen include the following:


- Fake driver’s licenses, which can create a multitude of related issues and have ramifications for the Department of Motor Vehicles
- Social Security fraud, whereby noncitizens gain entry into the United States illegally via stolen Social Security numbers and fake names
- Medical fraud, in which people use stolen personal information to obtain prescriptions or medical services
- Criminal identity theft, whereby thieves, using stolen identities, write bad checks, shoplift, and perform other illegal acts under an false identity
- Financial identity theft, in which stolen identity information is used to purchase goods and services in someone else’s name

These are all devastatingly time-consuming situations that happen daily in the world of identity theft. But they can be avoided or mitigated by using an identity theft protection and restoration product. Many companies have sprung up over the past few years offering protection from identity theft. One in particular, Lifelock, is adept at protecting its customers’ identities. Lifelock offers multiple protections within its program, including fraud alerts from major credit bureaus, as well as walletlock, which assists you in the event that your wallet is lost or stolen, among other protection services. On top of it all, Lifelock offers a \$1 million total service guarantee, which protects you if you are a Lifelock client and your identity is stolen or compromised; in all, the company will spend up to \$1 million to recover your good name. MDS Insurance Services (MDSIS) has negotiated a reduced-fee program for all Lifelock enrollees that is bundled with a prepaid legal and financial services hotline. So, for the many of us who have avoided signing up in the past, now might just be the right time.

Identity theft is the fastest-growing theft category in the world. If you want to learn more about protection against it, contact MDSIS at (800) 821-6033.

So, let me ask you again: Are you protected? If not, I have 150 million reasons for you to change that. ■





Horace Wells and His Significant Contributions to the Discovery of Anesthesia



**WILLIAM J. MALONEY, DDS
MAURA P. MALONEY, DDS**
Dr. William Maloney is group practice clinical coordinator at New York University College of Dentistry. He also maintains a private general dentistry practice in Ossining, NY. Dr. Maura Maloney is a general dentist in Westchester County, NY.

“Science brought a miracle for its relief worth more than all the miracles that had ever preceded it; and had placed it, as her generous custom is, within the reach of every sufferer, instead of restricting it to a pious half dozen, after the old way.”

—Samuel Clemens¹

Since the dawn of human consciousness, man has continuously sought various means of alleviating pain. Until the 19th century, these efforts had generally yielded poor results and could be viewed today as being quite primitive. Galen and Hippocrates employed the “soporific sponge” as an inhalation anesthetic. The sponge was impregnated with opium, henbane, and mandrake.² The Assyrians used strangulation as a method of pain relief for circumcisions.² The early 18th-century patient who required the amputation of a limb usually received a stiff dose of alcohol before the procedure.³

Dentistry could not have become the profession that it is today without the development of consistently safe and effective anesthetic drugs and techniques. The contributions of Dr. Horace

Wells played an extremely significant role in the discovery of anesthesia.

Horace Wells was born in the town of Hartford, Vermont, on January 21, 1815.⁴ He is descended from very aristocratic New England stock: His grandfather was

Captain Hezekiah Wells, who served in the American Revolution and was prominent in affairs of state.⁵ His grandmother was related to Jonathan Trumbull, the governor of Connecticut during the American Revolution.⁵

Dr. Wells trained as a dentist in Boston under a preceptor.³ In 1836, he opened his own dental practice in Hartford, Connecticut. His office was immediately successful, and he counted among his patients the more affluent and influential individuals of Hartford society.³ Dr. Wells was soon married to Elizabeth Wales and the couple had one child, Charles Thomas.

Despite his young age, Dr. Wells had two students of his own: John Mankey Riggs and William T. G. Morton,³ who would find immense notoriety and fame for their own achievements years later.

December 10, 1844, was a day which would change the course of Dr. Wells’s life forever. It would also be an extremely important day in the timeline of the development of anesthesia. Dr. Wells read in the December 10, 1844, edition of the *Hartford Courant* that there would be “a Grand Exhibition of the effects produced by inhaling nitrous oxide” that evening in Union Hall to be presented by Mr. G. Q. Colton.⁵ Dr. Wells and his wife decided to attend the exhibition that night.

Colton invited members of the audience to inhale the gas to experience its effects. One young man who volunteered hap-

pened to be sitting next to Dr. Wells. His name was Samuel Cooley, a young drug clerk.⁶

The masterful American author Samuel Clemens (better known by his pseudonym, Mark Twain) describes in his short story “Happy Memories of the Dental Chair” this momentous and historic event.¹ Clemens wrote, “They visited a traveling laughing-gas exhibition one winter night, and were consumed with laughter over the grotesque performances of some of the Hartford youth while under the happy dominion of the gas. Presently one of them, a young chap named Cooley, went sprawling over a chair or a table, and reached the stage with a crash, but immediately jumped up and plunged into the fun again with no diminution of spirit.”¹

Clemens did not make his residence in Hartford until many years after that fateful evening—well after Dr. Wells had passed on, but his vivid description of the events of the evening of December 10, 1844, were based on direct conversations with his own dentist and personal friend, Dr. John Riggs. Dr. Riggs would later become the first individual to limit his practice to periodontics and is considered to be the first specialist in this field.⁷

Dr. Wells contacted Colton after the nitrous oxide exhibition and asked him to bring the nitrous oxide to his office the next morning. Wells then contacted Dr. Riggs to discuss his experience at the nitrous oxide exhibition. The two discussed the possibilities of a nitrous oxide anesthetic. They decided that Dr. Riggs would extract one of Dr. Wells’s badly decayed molars the next morning.⁸

So it was that on December 11, 1844, at 10 a.m., history was made in Hartford. Present at the time in Dr. Wells’s office were five individuals—Drs. Wells and Riggs, Colton, Colton’s brother, and Sam Cooley.³ Dr. Riggs extracted the tooth as soon as Dr. Wells was under the influence of the nitrous oxide. Dr. Wells did not exhibit any signs of pain or discomfort.⁵ When Dr. Wells awoke from the anesthesia, he exclaimed, “It is the greatest discovery ever made! I didn’t feel it so much as the prick of a pin! A new era in tooth-pulling!”^{9,10}

Dr. Wells began experimenting with nitrous oxide and other gases for use as anesthetics. He experimented with ether but favored nitrous oxide, which he con-

sidered to be safer.³ Dr. Wells continued to have much success with using nitrous oxide on his patients, and then he set his sights on Boston. Boston was a medical hub of great importance, with the presence of Harvard Medical School and Massachusetts General Hospital.

Boston Bound

On January 20, 1845, Dr. Wells lectured to the senior medical students of Dr. John Warren at the Massachusetts General Hospital.⁵ Dr. Wells then proceeded to extract a tooth from a volunteer. The administration of the gas went well, and the extraction was performed quickly, but as the tooth came out, the patient groaned. The audience laughed and hissed.² A former student of Dr. Wells’s, Dr. William Morton, was in the audience.

Unfortunately, after this demonstration Dr. Wells felt ridiculed and was never the same person from that point on. He would go on to practice dentistry only on a sporadic basis.⁸ On October 16, 1846, Dr. Morton, that former student, successfully anesthetized a patient with ether at the Massachusetts General Hospital. Soon after, Dr. John Warren proceeded to remove a small tumor from the neck of a young man who experienced no pain during the surgery. Dr. Warren declared, “Gentlemen, this is no humbug.”²

After Dr. Morton’s success, Dr. Wells fell into a deep depression and tried for the remainder of his life, in an obsessive manner, to prove his very significant role in the discovery of anesthesia. On January 21, 1848, Dr. Wells was arrested in New York City for throwing sulfuric acid in the faces of two females. While in prison, at the age of 33, he committed suicide by slashing his femoral artery.⁸ Ironically enough, he anesthetized himself with chloroform prior to this act.⁵

Dr. Horace Wells had many honors bestowed upon him posthumously. Among these honors is the inclusion of Dr. Horace Wells in the Pierre Fauchard Academy International Hall of Fame of Dentistry. He deserves the praise of both members of the scientific community and grateful patients worldwide.

Today, a magnificent statue of Dr. Wells stands in the east section of Bushnell Park in Hartford. The statue gazes peacefully and proudly across the green landscape, giving no indication as to Wells’s tumultuously short life. ■

References

1. Twain, M. Happy memories of the dental chair. In: Hirst RH, editor. Who is Mark Twain? New York (NY): HarperCollins; 2009. p. 77-85.
2. Goldsmith D. The discovery of anesthesia. *Anesth Prog.* 1974;174-180.
3. Carranza, FA. The discovery of anesthesia: the tragic history of Wells and Morton. 2009. Available from: <http://www.dent.ucla.edu/pic/members/carranza/anesthesia.html>
4. Pierre Fauchard Academy International Hall of Fame of Dentistry. Dr. Horace Wells. 2009. Available from: <http://www.fauchard.org/awards/fame3.htm>
5. Jacobsohn PH. Horace Wells: discoverer of anesthesia. *Anesth Prog.* 1995;42:73-75.
6. Finder, SG. Lessons from history: Horace Wells and the moral features of clinical contexts. *Anesth Prog.* 1995;42:1-6.
7. Shklar G, Carranza FA. The historical background of periodontology. In: Newman MG, Takei HH, Carranza FA, editors. Carranza’s clinical periodontology, 9th ed. Philadelphia (PA): W.B. Saunders; 2002. P. 7.
8. Wildsmith JAW, Menczer LF. A British footnote to the life of Horace Wells. *Br J Anaesthes.* 1987;59(9):1067-1069.
9. Colton GQ. Deposition of G.Q. Colton, of the city of New York. In: Smith T, editor. An examination of the question of anaesthesia, arising on the memorial of Charles Thomas Wells, presented to the United States Senate, second session, Thirty-Second Congress, and referred to a select committee, of which the Hon. Isaac P. Walker is chairman. New York (NY): John A. Gray, Printer; 1858. p. 22-23.
10. Riggs JM. Extract from the deposition of John M. Riggs, dentist of Hartford, Connecticut. In: Smith T, editor. An examination of the question of anaesthesia, arising on the memorial of Charles Thomas Wells, presented to the United States Senate, second session, Thirty-Second Congress, and referred to a select committee, of which the Hon. Isaac P. Walker is chairman. New York (NY): John A. Gray, Printer; 1858. p. 21-22.



Root Resorption and Irreversible Damage to the Paradental Structures Associated with Orthodontic Treatment

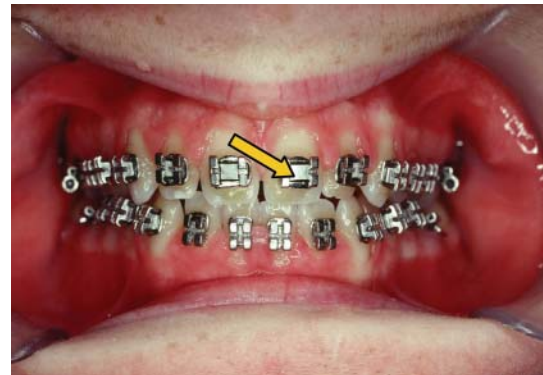

Figure 1. Edgewise brackets. Arrow designates labial slot for archwire insertion.

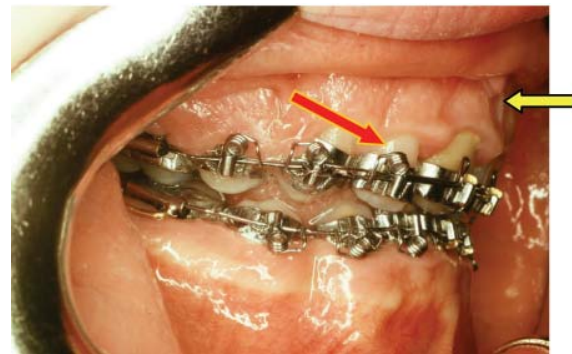

Figure 2. Begg brackets. Note the excessive tipping of the incisors, which likely produced fenestrations of the labial plate, indicated by the yellow arrow. The red arrow designates gingival slot access for archwire insertion.

Abstract

Modifications of orthodontic appliances and mechanotherapy have evolved continually over the past several decades. General practitioners have observed the changes in appliance design in their own patients in treatment by local orthodontists. This article discusses state-of-the-art orthodontic biomechanics and appliance design, and the impetus that has led many clinicians to adopt biomechanically sound treatment innovations that avoid damage to dental roots and their supporting tissues.

VINCENT DEANGELIS, DMD

Dr. DeAngelis has served as the editor of the *Northeastern Society of Orthodontics*, associate clinical professor of orthodontics at *Harvard School of Dental Medicine*, president of the *Massachusetts Society of Orthodontics*, and president of the *Edward H. Angle Society of Orthodontists, Eastern Component*. He is a recipient of the *Outstanding Teacher Award from the Harvard Society for the Advancement of Orthodontics* and the *Frederick Moynihan Award from the Massachusetts Association of Orthodontists*, and he is a *Fellow of the International College of Dentistry*.

Introduction

In the early 1900s, the Edgewise Technique was the predominant orthodontic treatment of choice. This appliance was then and is still now practiced worldwide, and has been extensively described by Thurow.¹

The Edgewise bracket design accommodates both round and rectangular cross-section archwire (see Figure 1). The latter's capability permits torqueing—exerting control over the labiolingual movement of dental roots while maintaining stationary crown positions. The rectangular-shaped archwire engages the rectangular Edgewise slot to achieve this essential form of tooth movement. The round cross-section archwires are unable to produce this important form of dental manipulation.

In the 1950s, Dr. P. Raymond Begg of Adelaide, Australia, introduced a then-revolutionary method of orthodontic treatment, solely utilizing round cross-section archwires, which were inserted into a narrow, gingivally accessible bracket, versus the common labially accessible bracket.² Vertical pins to affix the archwires to the bracket replaced the wire ligation of the Edgewise appliance. This technique heralded rapid treatment results requiring fewer visits and longer intervals between appointments. Through a series of uncontrolled tipping movements, bite opening, dental alignment, and protrusions were resolved relatively quickly (see Figure 2). In the Begg technique, torque was achieved with an auxiliary “piggy back” sectional round wire.

Another advantage of the technique purported by Begg was the elimination of the need for headgear for correction of the ubiquitous Class II malocclusion. Consequently, this method relied heavily on four premolar extractions and often the extraction of maxillary permanent first molars, as well—six tooth extractions—since distalization of the maxillary arch for Class II

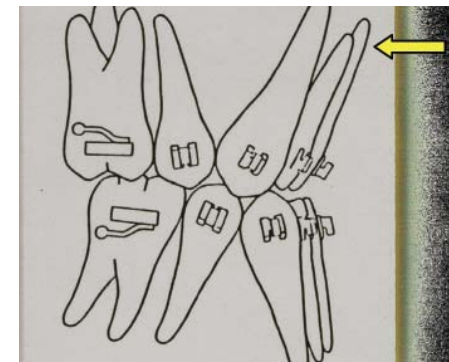


Figure 3. A similar excessive uncontrolled tipping with Edgewise brackets (arrow points to location of potential fenestration). Poor biomechanics, not the appliance, is responsible for this tissue damage.

correction was not an objective of the Begg treatment. The Class II molar relationship was resolved primarily by dentoalveolar means. Therefore, treatment characteristically did not begin until the late mixed dentition or the early permanent dentition period of dental development.

Variations of the Begg appliance were introduced in the Tip-Edge technique by Kesling, where the brackets were modified for more control, incorporating an Edgewise component to the previous Begg pin-in-tube design.³ The Edgewise bracket edges were chamfered to facilitate uncontrolled tipping of the teeth in keeping with the Begg treatment philosophy (see Figure 3). Elastomeric ties to fix the archwires to the bracket replaced the vertical pin connection of the Begg appliance.

In 1976, Andrews modified the Edgewise bracket design, incorporating torque, angulations, and varied dimensions of the slot, obviating the need for adding these features by previously required archwire manipulation.⁴ In reducing the archwire bending requirement, this innovation was an attempt to facilitate treatment, reduce chair time, and gain greater precision in the treatment outcome. Later, Roth modified the Andrews bracket.⁵ The resulting Straight Wire Appliance of Andrews and Roth has been universally adopted by the international orthodontics community for decades and its popularity continues today.

Discussion

As these various disparate treatment modalities evolved, problems inherent in all became evident. Radiographic evidence of root resorption, reported by Ketcham in 1927,⁶ has been viewed as an unpre-

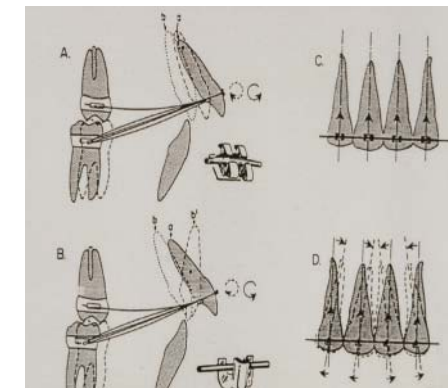


Figure 4. Diagram depicting controlled tipping versus uncontrolled tipping, sagittally and transversely. Uncontrolled tipping requires subsequent uprighting. Outlines of Edgewise and Begg brackets are shown.

dictable and unavoidable negative side effect of orthodontic treatment, and it remains a concern of dentistry today. It seems apparent to many that root resorption is an inevitable consequence of orthodontic treatment. Current orthodontic literature is replete with research on the etiology and pathogenesis of this irreversible damage to the root apices. The Begg system, with its reliance on uncontrolled tipping of all teeth, employed the inefficient practice of roundtripping—redundant movement of root apices in one direction only to require later movement in the opposite direction during treatment of a malocclusion (see Figure 4). The Kesling modification did little to resolve this problem. Irreversible damage to the root apices in the form of root resorption and production of fenestrations and dehiscences in the alveolar bone often resulted from these superfluous, redundant root

movements produced by uncontrolled tipping of teeth.^{6,7}

The Straight Wire Technique has similar shortcomings. This comparatively rigid method of mechanotherapy added rectangular wire roundtripping to round wire roundtripping. As rectangular archwires engage pretorqued Edgewise brackets, Newton's third law of physics applies, since incisor lingual root torque, often an integral component of orthodontic treatment, inevitably creates buccal premolar and molar root torque (see Figure 5). This latter consequential movement of the roots risks the occurrence of buccal plate fenestrations. Wehrbein et al. reported evidence of this damage to the roots and paradental tissues in their gross and histological analysis of a deceased 19-year-old orthodontic patient, a traffic accident victim who had been treated for approximately one year with the Straight Wire Appliance. From their findings, they stated that “the buccal periosteum draped like an awning over the exposed, severely resorbed molar root apices and the palatal roots perforated the maxillary sinus.”⁹ Correlation of treatment duration with the Roth Straight Wire Appliance to irreversible tissue damage was further revealed by the 1991 Kaley and Phillips study of 200 consecutively treated patients where 90 percent of these patients were found to exhibit varying degrees of incisor apical root resorption. Moreover, they found a strong positive correlation between the amount of resorption and the length of time the patient was treated by intraslot

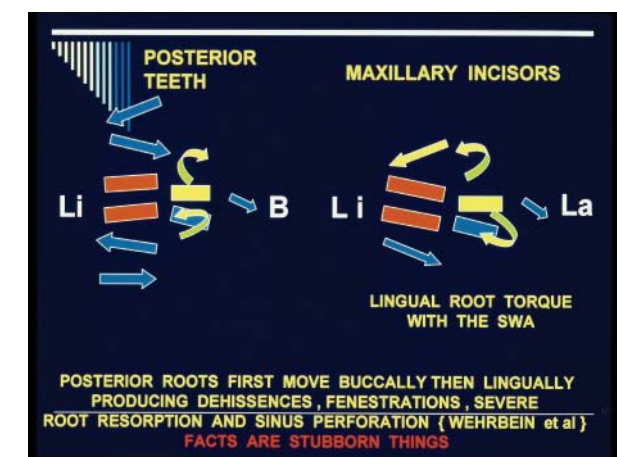


Figure 5. Diagram demonstrates that incisor palatal root torque produces buccal root torque of posterior teeth as the rectangular archwire (yellow) is twisted to engage the Edgewise attachments. Newton's third law of physics applies. Wehrbein et al. show the severe adverse effects of these mechanics in a human subject.⁹

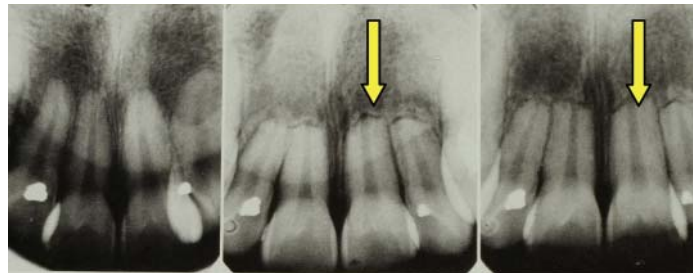

Figure 6. Radiographs reveal moderate to severe incisor root resorption following Straight Wire Appliance treatment. Subsequent alveolar bone loss can result in loss of these teeth. Image from Kaley and Phillips.¹⁰

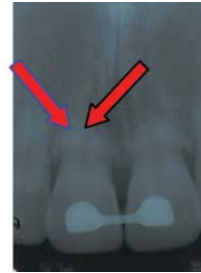


Figure 7. Severe incisor root resorption following the Straight Wire orthodontic treatment of a 25-year-old patient. A splint is in place to stabilize the extremely short roots. Extent of root resorption is designated by the arrows. Risk of tooth loss is increased, particularly if there is subsequent periodontal breakdown.

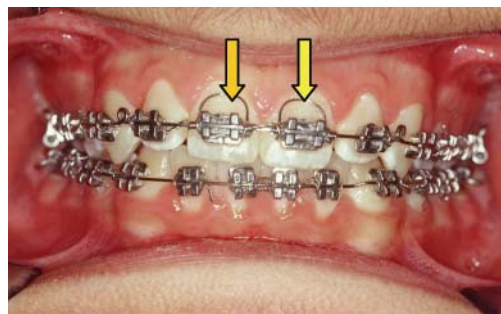


Figure 8. Warren spring auxiliaries utilized in the Amalgamated Technique apply gentle torque to move the incisor roots palatally. Posterior teeth are not adversely affected with this method, as the narrow rectangular archwire does not engage the wider posterior attachments, which would create buccal plate fenestrations. The posterior archwire extensions "roll" within the wider attachments, avoiding roundtripping, vis-à-vis intraslot torque, with the Straight Wire Technique.

torqueing with rectangular archwire¹⁰ (see Figure 6).

Recently, the trend toward self-ligating brackets has eliminated the practice of wire ligation entirely, to reduce chair time. This innovation, however, does little to improve treatment outcomes and possibly even exacerbates the root resorption problem.

Conclusions and Recommendations

Some lessons learned from a critical review of the evolution of orthodontic appliances are clear and simple. The clinician must avoid roundtripping of teeth in all three planes (vertical, sagittal, and transverse); use light, physiologic continuous forces; and keep treatment time as short as possible, particularly with rectangular archwires that engage the Edgewise slots. In fact, total elimination of that form of incisor torque is prudent.¹ By adhering to these tenets, the orthodontist limits irreversible damage to teeth and supporting structures,

occurrences that lead to the premature aging of the dentition and the risk of incisor loss when compounded by reduced alveolar bone level with time.¹⁰ Root apices must be moved in one direction only once, whether round or rectangular archwires are utilized. This essential rule is attainable if the clinician carefully applies sound biomechanics to the dentition, and does not allow the appliance to dictate the mechanotherapy for expedience.

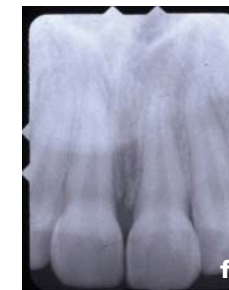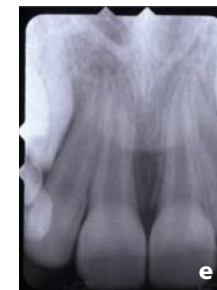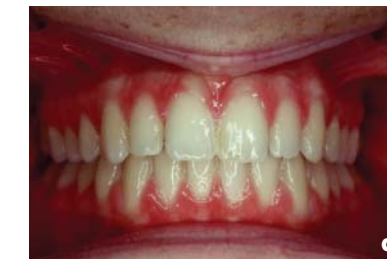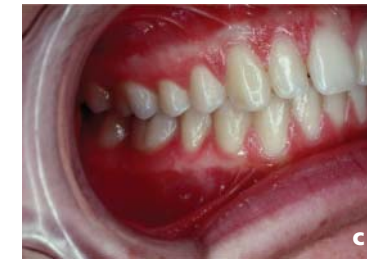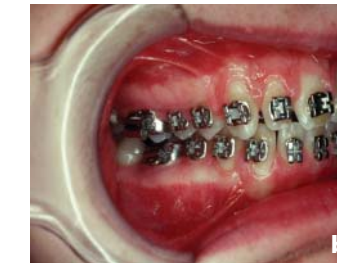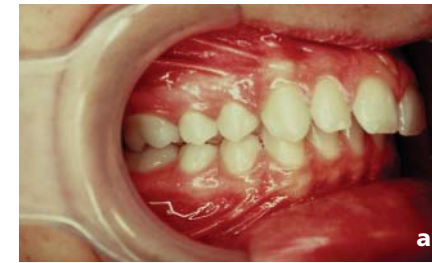Techniques that focus on the elimination of root roundtripping by avoiding all superfluous root apex movement are currently practiced by many discerning clinicians. Roots of anterior and posterior teeth must be carefully moved only once to their final position in all three planes. Accomplishing this objective curtails irreversible damage to roots and paradental structures associated with orthodontic treatment¹¹⁻¹³ (see Figure 7). Moreover, elimination of intraslot torque where the rectangular archwire fills or engages the Edgewise slot to some degree avoids the severe adverse effects reported

by both the Wehrbein and Kaley and Phillips studies.^{9,10} In fact, Thurow advocates the total elimination of this popular rectangular archwire intraslot torque¹ (see Figure 5). This principle can be accomplished by the use of torqueing auxiliaries as employed in the Amalgamated Technique (AT)¹¹ (see Figure 8).

In the AT, the clinician carefully aligns the clinical crowns without any redundant root movements, utilizing a combination of round and rectangular archwires. With the round cross-section archwire utilized early in AT treatment, controlled versus uncontrolled tipping of teeth is attained to prevent superfluous movement of root apices. (see Figure 4). Moreover, the rectangular wires employed later in treatment do not engage the rectangular Edgewise bracket slots since, unlike in the Straight Wire Technique and the many other methods that rely on intraslot engagement of the bracket for torque, these wire dimensions are considerably smaller (.016" x .018") than the wider-dimension Edgewise slot (.022" x .028") of the AT. Instead, torque with the AT is achieved with the gentler auxiliary torqueing springs that avoid the roundtripping of posterior teeth because the posterior archwire extensions, owing to their undersize, do not engage the posterior attachments to attain the necessary incisor torque. These extensions "roll" within the slots while the torqueing auxiliaries apply light, continuous force to the incisors, thereby avoiding the adverse affects (i.e., buccal fenestrations and apical root resorptions of the posterior teeth) described by Wehrbein⁹ (see Figure 5).

In essence, the brackets utilized in all appliances should simply be considered as handles made available to move teeth, just as the golf club is the instrument that moves the golf ball. The biomechanical application to these instruments determines the final outcome. In the absence of sound biomechanics, the bracket and golf club are irrelevant and may even be detrimental in determining the result.

Basically, root resorption in orthodontics is analogous to the dreaded shanked shot in golf. If one employs sound mechanical and biological techniques, both potentially devastating outcomes can be avoided. The success of orthodontic treatment should not be



Figures 9a-9f. Class II, Division 1 patient treated for 18 months with controlled light continuous biomechanics (Amalgamated Technique), thus avoiding roundtripping in three planes (Figures 9a-9d). Pre- and posttreatment periapical radiographs reveal the total absence of root resorption (Figures 9e-9f). Controlled root apex movements throughout treatment also eliminate the likelihood of fenestrations of the labial and buccal plates.

measured only by posttreatment dental casts, photographs, and gross examination while ignoring a thorough examination of radiographic evidence of irreversible root and paradental soft- and hard-tissue destruction directly related to orthodontic treatment. Only after including final periapical radiographs in post-treatment records that confirm the absence of irreversible damage to the roots and periodontium can the orthodontic result be deemed truly successful (see Figures 9a-9f). ■

References

1. Thurow R. Edgewise orthodontics. St. Louis (MO): Mosby; 1966.
2. Begg PR, Kesling PC. Begg orthodontic practice and technique. Philadelphia (PA): W.B. Saunders; 1977.
3. Kesling PC. Expanding the horizons of the Edgewise arch wire slot. Am J Orthod Dent Facial Orthop. 1988;94:27-37.
4. Andrews LF. The straight-wire appliance: origin, controversy, commentary. J Clin Orthod. 1976;10(2):99-114.
5. Roth RH. The straight wire appliance 17 years later. J Clin Orthod. 1987;21:632-642.
6. Ketcham AH. A preliminary report of an investigation of apical root resorption of permanent teeth. Int J Orthod. 1927;13:97-127.
7. Ten Hoeve A, Mulie RM. The effect of antero-postero incisor repositioning on the palatal cortex as studied with laminography. J Clin Orthod. 1976;11:804-822.
8. Goldson L, Hendrickson CO. Root resorption during Begg treatment: a longitudinal roentgenologic study. Am J Orthod. 1975;73:55-66.
9. Wehrbein H, Fuhrmann RAW, Deidrick PR. Human histological tissue response after long-term tooth movement. Am J Orthod Dentofac Orthop. 1995;107:360-371.
10. Kaley J, Phillips C. Factors related to root resorption in Edgewise practice. Angle Orthodont. 1991;61:125-132.
11. DeAngelis V. Begg-Edgewise: an amalgamated technique. Am J Orthod. 1976;69:301-317.
12. DeAngelis V. The amalgamated technique: a mechanically and biologically efficient method of controlled tooth movement. Angle Orthodont. 1980; L(1):1-15.
13. DeAngelis V, Davidovitch Z. Optimal orthodontics: an achievable target. In: Krishan V, Davidovitch Z, editors. Biological methods of tooth movement. Oxford (UK): Wiley-Blackwell. 2009. p. 180-200.

RDH TEMPS
NO HASSLES. NO WORRIES. THE RESOURCE FOR DENTAL HIRING.
www.rdhtemps.net
1-800-462-TEMP OR 1-888-RDH-TEMP
Serving CT, MA, NH and RI



Flexibility.

- Temporary and permanent staffing exclusively for the dental industry.
- Dentists, Dental Hygienists, Dental Assistants and Administrative Staff.
- Centrally owned and operated since 1979 with local specialists.
- Flexible temporary rates; proportional rebates should a permanent placement fail to last.
- All dental auxiliary and administrative temps are our employees.
- Personnel are interviewed in person and are pre-screened.
- Extensive live phone coverage by a large team of staffing experts.
- RDH Temps carries professional liability (malpractice) insurance on all Dental Hygienists & Assistants.

New!
Flexible rates!
Proportional management fees!
No daily overtime!
70% of customers will save an average of \$19 per day!



General Manifestations of Behçet's Syndrome and the Success of CO₂-Laser as Treatment for Oral Lesions: A Review of the Literature and Case Presentation

**NEOPHYTOS DEMETRIADES, DMD, FROMS
HOPE HANFORD, BA
CONSTANTINOS LASKARIDES, DMD, PHARM D**

Dr. Demetriades is an instructor in the department of oral and maxillofacial surgery, Ms. Hanford is a dental student, and Dr. Laskarides is an assistant professor in the department of oral and maxillofacial surgery at Tufts University School of Dental Medicine.

Abstract

This article reviews the oral manifestations of Behçet's Syndrome that have been discussed in the literature and presents the success of the use of CO₂-laser for recurrent aphthous stomatitis (RAS). Behçet's Syndrome is a multisystem inflammatory disease that has the capacity to affect nearly every human system. It is characterized by a wide range of clinical features. In particular, the defining symptom in most cases is recurrent aphthous stomatitis present in the oral cavity. RAS is the most common inflammatory ulcerative condition to affect the oral cavity and is characterized by localized, painful ulcers that may be a manifestation of more complicated diseases, such as Behçet's Syndrome. There is no effective treatment for RAS. In most cases, RAS is managed by anesthetic topical treatments, topical or systemic steroids, or antibiotics. More recently, though, there has been evidence of possible benefit from treatment of aphthous lesions with CO₂-lasers. Our experience treating a patient who suffered from Behçet's Syndrome and RAS showed transient pain relief with the use of CO₂ ablative laser as a monotherapy.

RAS lesions are localized, painful, shallow ulcers that afflict the soft mucosa of the oral cavity.¹ According to the literature, anywhere from 5 to 25 percent of the population is affected by RAS ulcerations.² The precise etiology and pathophysiology of RAS are unknown. However, many predisposing circumstances are known, such as genetic factors, immunological problems, hypersensitivity to food and drugs, hormonal changes, trauma, and environmental and psychological stresses.² Recurrent aphthous lesions may also be the manifestation of more complicated diseases such as Behçet's Syndrome. While the most common clinical feature of Behçet's Syndrome is RAS in the oral cavity, the clinical manifestations may extend to the skin, genital area, and eyes; in severe cases, Behçet's Syndrome may also include vascular and neurological involvement (see Table 1).

There is no cure for RAS, so the majority of treatments focus on relief of localized symptoms. Remedies for aphthous ulcerations include topical corticosteroids, mouthrinses, antibiotics, or local anesthetic gels.² More recently, CO₂-lasers have been used to treat the localized symptoms of RAS. Zand et al. proved in a randomized control study of 15 patients where all of the patients treated with a nonablative, nonthermal CO₂-laser reported a significantly lower level of pain in comparison to placebo ulcerations and following treatment, and 100 percent of patients required no postoperative medication.² A similar study completed by Colvard and Kuo used an ablative CO₂-laser requiring anesthesia and was able to eradicate pain in 88.8 percent of the cases.³ Much of the literature indicates that CO₂-laser treatment could be considered as an alternative relief for RAS.

In this article, we will review the existing literature and present a case in which CO₂-laser ablation was used to treat aphthous ulcerations on a patient diagnosed with Behçet's Syn-

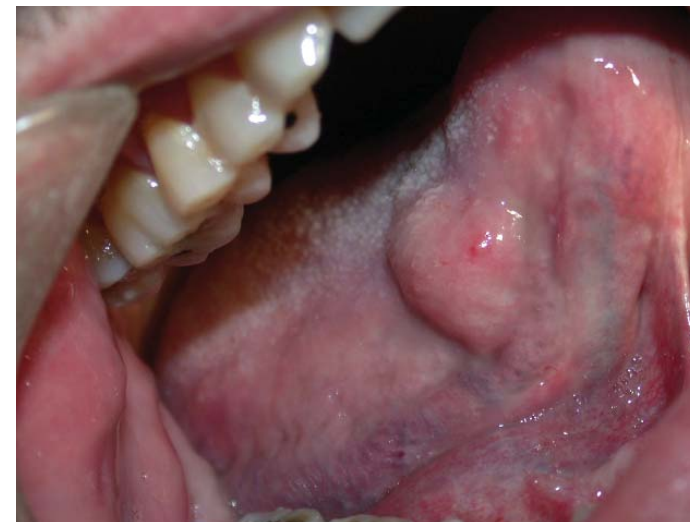

Figure 1. Ulcerative lesions on the right floor of the mouth.

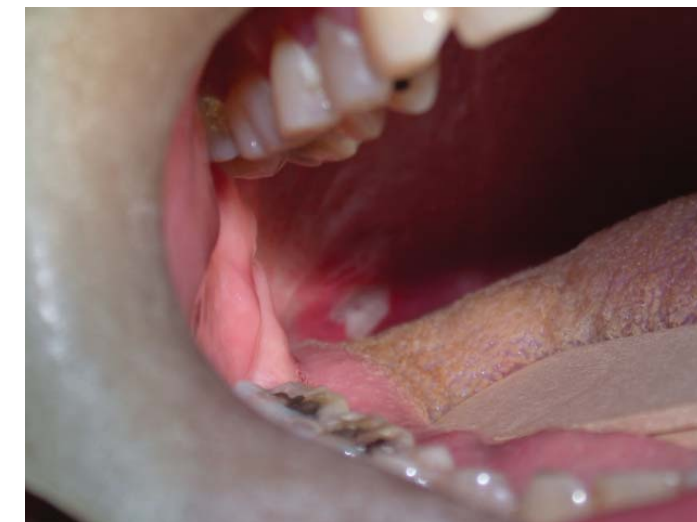

Figure 2. Ulcerative lesions on the right lateral pharyngeal wall.

drome. Furthermore, clinical and laboratory diagnosis of Behçet's Syndrome will be presented, and the more common manifestations of the disease will be discussed.

Case Report

A 53-year-old male patient presented to the department of oral and maxillofacial surgery at Tufts University School of Dental Medicine. The patient's oral condition had been consistently problematic since 1981. His clinical symptoms included persistent oral and oropharyngeal ulcerations (major apthae), which impeded daily functions, including swallowing, drinking fluids, eating, talking, and sleeping. He also suffered from ocular and genital lesions, which were clinically consistent with Behçet's Syndrome.

The patient had a medical history of hypercholesterolemia and depression. The patient also suffered from dilated cardiomyopathy due to the involvement of the myocardium by the disease; severe pain in the legs and feet as a result of joint lesions; burning sensation in the eyes due to ocular lesions; and increased peripheral neuropathy and tinnitus consistent with Behçet's Syndrome. The patient had a 35-year history of recurrent major aphthous stomatitis with high frequency, severity, and duration. Many unsuccessful treatments had been attempted, including administration of steroids and thalidomide. The only marginally successful treatment for the lesions has been a high dosage of corticosteroids, which have had significant side effects.

The patient was referred to our service for laser ablation of prodromal lesions. On clinical examination, four regions were dominated by ulcerative lesions: the right floor of the mouth (see Figure 1), the right lateral pharyngeal wall (see Figure 2), the right lateral tongue, and the alveolar mucosa buccal to tooth #6 (see Figure 3). The significant pain and discomfort of the patient, in combination with the failure of the current treatments, led to the decision to use the CO₂-laser as a treatment for the RAS.

The patient was treated in the outpatient setting under local anesthesia (see Figure 4). All appropriate laser safety measures were observed. The involved areas were infiltrated with a minimal amount of lidocaine 2% with 1:100,000 epinephrine. A CO₂-laser set at low-power

Table 1. Manifestations of Behçet's Syndrome

Article	Authors	Journal	Manifestations Presented in Article
Adamantiades-Behçet Disease: An Enigmatic Process with Oral Manifestations ⁴	Eguia A, et al.	Med Oral Patol Oral Cir Bucal	Recurrent oral ulcers, genital lesions, ocular lesions, joint lesions, neurological lesions, vascular lesions, gastrointestinal lesions, and other complications (cardiac, renal, pulmonary, and pleurae)
Recurrent Aphthous Stomatitis in the Diagnosis of Behçet's Disease ¹	Rogers RS 3rd	Yonsei Med J	Oral recurrent aphthous stomatitis, genital ulcers, and ocular inflammation
Diagnostic Criteria of Behçet's Disease: Problems and Suggestions ⁶	Lee S	Yonsei Med J	Oral, ocular, and genital lesions, arthritis, gastrointestinal lesions, epididymitis, vascular lesions, and central nervous system symptoms
Behçet's Disease ⁵	Kontogiannis V, Powell R	Postgrad Med J	Oral ulcers, genital ulcers, skin lesions, arthritis, fatigue, widespread vasculitis, arterial aneurysms, and neurological, gastrointestinal, brain, and audiotestibular symptoms

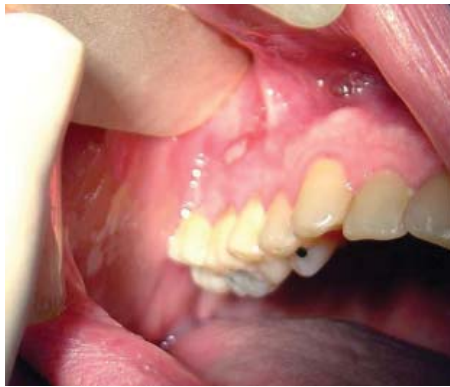

Figure 3. Lesions on the alveolar mucosa.

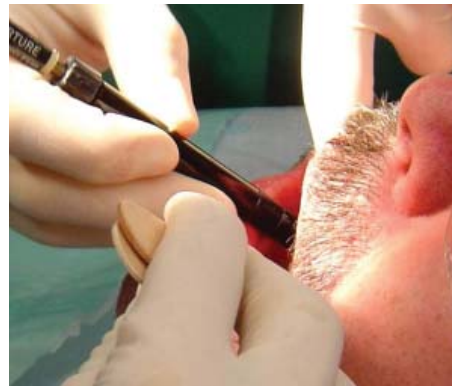

Figure 4. CO₂-laser set at low-power (2W) superpulse mode with a 0.4 mm ceramic tip was used to lightly char the surface.

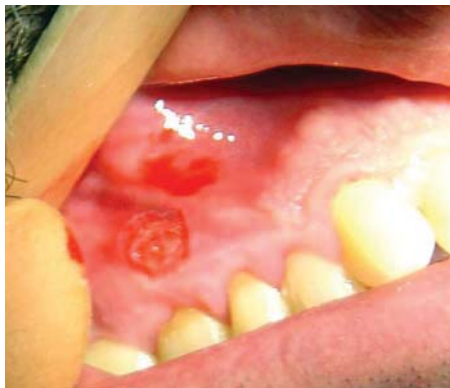

Figure 5. Ulcerative lesions immediately following CO₂-laser ablation.

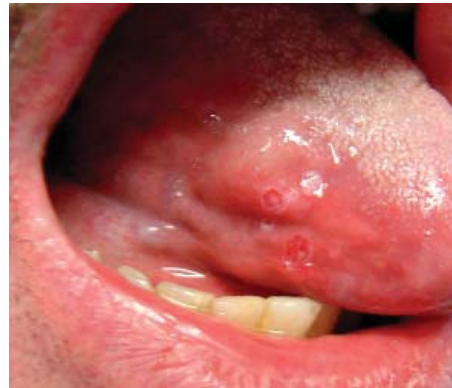

Figure 6. Lesions at one-week follow-up, at which time the patient reported considerable relief of symptoms.

(2W) superpulse mode with a 0.4 mm ceramic tip was used, after calibration, in a defocused way to lightly char the surface of the ulcers (see Figures 4 and 5). The patient tolerated the procedure well. On subsequent follow-up, one week after the procedure, the patient reported considerable relief of symptoms on most of the treated ulcers (see Figure 6). The oropharyngeal ulcer displayed only moderate response, but the patient reported an overall improvement of his quality of life. On long-term observation, two months after the procedure, most ulcers had disappeared and the oropharyngeal area, although clinically improved, remained mildly symptomatic. Six months after his original treatment, the patient developed more intraoral aphthous ulcers.

Overall, the CO₂-laser helped to decrease the sensitivity and control the pain for a short period of time. No healing of the ulcerative lesions was appreciated. In our experience, CO₂ ablative lasers can be used for pain control in Behçet's Syndrome patients with some transient benefits.

Discussion

Behçet's Syndrome is a multisystem inflammatory reaction that has the capacity to affect any human organ or system. The disease is characterized by recurrent cycles of remission and relapse, as well as a wide range of clinical features. At one time, the Pathergy Test was used as a diagnostic tool for the disease; however, in many cases it can give a false negative result.^{4,5} To date, there is no conclusive diagnostic test for Behçet's Syndrome, so diagnosis relies solely on the wide range of clinical features. Oral and genital aphthous ulcerations are the most common manifestation of Behçet's Syndrome. However, alone they are not evidence enough for diagnosis of Behçet's Syndrome.

According to Eguia et al., the International Study Group for Behçet's Syndrome established a classification in 1990 that would provide evidence for the disease based on at least three episodes of oral ulcers within a 12-month period and the presence of at least two of the following manifestations: repeated geni-

tal ulcers, ocular lesions, cutaneous lesions, or a positive patergy test.⁴ Despite the fact that numerous other classification schemes have been developed over the years, no consistent model exists today.^{4,6} Therefore, it is essential to develop a comprehensive clinical history of the patient in order to establish differential diagnosis along with the potential diagnosis of Behçet's Syndrome.

According to Kondogiannis and Powell, oral ulcers are the defining feature in 97 to 100 percent of the cases and the initial symptom in most cases.⁵ Clinically, the oral lesions of Behçet's Syndrome are indistinguishable from RAS.⁴ Therefore, the clinician must be cognizant of defining characteristics of associated RAS systemic disorders.¹ The oral ulcers found in Behçet's Syndrome are typically limited to the nonmasticatory oral mucosa.¹ Eguia et al. classified the oral ulcers of Behçet's Syndrome into three main categories: minor ulcers (less than 1 cm), major ulcers (larger than 1 cm), and herpetiform (1–3 mm).⁴ In many cases, oral ulcers may appear one to three years before any other symptoms.

Less common manifestations of Behçet's Syndrome include genital, cutaneous, ocular, joint, neurological, and vascular lesions. According to Eguia et al., genital lesions occur in 60 to 80 percent of patients, cutaneous lesions occur in 80 percent, ocular lesions occur in 20 to 50 percent, joint lesions occur in 40 to 50 percent, and neurological lesions occur in 5 to 20 percent.⁴ Genital lesions are extremely painful and can result in difficulty with walking. Ocular lesions may result in conjunctivitis, vasculitis, or retina atrophy or loosening. According to Kondogiannis and Powell, ocular involvement can result in vision loss for 25 percent of patients who experience ocular manifestations.⁵

In general, Behçet's Syndrome is characterized by a widespread vasculitis, which can result in a tendency toward thrombosis in many patients. While neurological involvement is less common, it can result in brain and spinal cord damage or emotional and sensory changes.^{4,5} Arterial aneurysms can result from vasculitis and can be potentially lethal. Gastrointestinal lesions are rare and may result in a variety of symptoms, including abdominal pain, dysphagia, and diarrhea.

Table 2. Previous CO₂-laser Studies Completed

Article	Authors	Journal	Study Completed	Number of Patients	Success Rate
Relieving Pain in Minor Aphthous Stomatitis by a Single Session of Non-thermal Carbon Dioxide Laser Irradiation ²	Zand N, et al.	Lasers Med Sci	Single-session non-thermal CO ₂ -laser on relieving pain in minor recurrent ulcers	15	100%
Managing Aphthous Ulcers: Laser Treatment Applied ³	Colvard M, Kuo P	JADA	Ablative CO ₂ -laser on relieving pain in recurrent ulcers	18	88.8%
CO ₂ -laser Treatment of Ulcerative Lesions ⁷	Sharon-Buller A, et al.	Oral Surg Oral Med Oral Path Oral Radiol Endod	CO ₂ -laser therapy for relieving pain in large lesions in the oral cavity	2	100%

The distinct difference between the ulcers of RAS and Behçet's Syndrome remains unclear. RAS is the most common inflammatory ulcerative condition of the oral mucosa.¹ RAS lesions are typically shallow, painless, round-to-oval ulcers.¹ Rogers states that the presence of RAS lesions is critical in the diagnosis of Behçet's Syndrome.¹ However, Eguia et al. indicate the disparity between RAS and Behçet's Syndrome ulcers, explaining that Behçet's Syndrome ulcers tend to appear in unusual places and in higher numbers.⁴ Nevertheless, both forms of ulcers appear to be aphthous in nature and are managed with similar techniques.

In the past, oral aphthous lesions have been treated with anesthetic pastes and mouthwashes, topical or systemic steroids, and antibiotics.⁷ Topical and systemic treatments help to reduce the symptoms and duration of the ulcers, but are not effective in preventing recurrences.⁴ Immunosuppressive drugs, such as thalidomide, are effective in decreasing the number of lesions and the length and severity of ulcers, as well as in increasing the latency period.⁴ However, these drugs can have severe side effects.

Most of these remedies only help to provide temporary pain relief to localized symptoms and do not help to prevent future occurrences. Recently, CO₂-lasers have been considered in order to relieve the symptoms of aphthous lesions. Studies have proven that CO₂-laser therapy has been effective in relieving pain from aphthous lesions.^{2,3,7} The precise mechanism

by which CO₂-lasers are able to effectively reduce pain is unknown. However, Zand et al. provide some of the explanations: the blockage of action potential and conduction of nociceptive signals in afferent neurons; a decrease in the release of chemical mediators; and an increase in the amount of natural analgesics.¹

Conclusion

In the three studies considered, the reduction in pain was significantly greater immediately following laser treatment of aphthous lesions (see Table 2). However, the studies did not indicate whether the decrease in pain was long lasting. In a randomized, controlled study of 15 patients, Zand et al. proved a significant decrease in pain among the treated lesions in comparison to the placebo lesions; however, pain measurements were only taken up to 96 hours after treatment.² In a separate study by Colvard and Kuo, pain measurements were only taken immediately after resolution of anesthesia; however, it was reported that all lesions had healed within 7 to 10 days.³

All three studies indicate evidence that lesions are less likely to occur at the treated site.^{2,3,7} In addition, the studies excluded patients who had any systemic disease, including Behçet's Syndrome, that may have predisposed them to RAS. Although there is significant evidence that recurrent aphthous ulcerations respond positively to CO₂-laser treatment, more research must be completed in regard to aphthous lesions in Behçet's Syn-

drome before any recommendation can be made for the use of CO₂-lasers on Behçet's Syndrome ulcerations. Our experience follows existing literature (see Table 1) and shows that CO₂-lasers can offer a transient relief of symptoms when used as monotherapy for treatment of RAS. ■

References

- Rogers RS 3rd. Recurrent aphthous stomatitis in the diagnosis of Behçet's disease. *Yonsei Med J.* 1997;38:370-379.
- Zand N, et al. Relieving pain in minor aphthous stomatitis by a single session of non-thermal carbon dioxide laser irradiation. *Lasers Med Sci.* 2008;24:515-520.
- Colvard M, Kuo P. Managing aphthous ulcers: laser treatment applied. *JADA.* 1991;122:51-53.
- Eguia A, et al. Adamantiades-Behçet disease: an enigmatic process with oral manifestations. *Med Oral Patol Oral Cir Bucal.* 2006;11:E6-E11.
- Kontogiannis V, Powell R. Behçet's disease. *Postgrad Med J.* 2000;76:629-637.
- Lee S. Diagnostic criteria of Behçet's disease: problems and suggestions. *Yonsei Med J.* 1997;38:365-369.
- Sharon-Buller A, et al. CO₂-laser treatment of ulcerative lesions. *Oral Surg Oral Med Oral Pathol Oral Radiol Endod.* 2004;97:332-334.

Have a Question or Comment?

To contact our editorial department, write to JOURNAL OF THE MASSACHUSETTS DENTAL SOCIETY, Two Willow Street, Suite 200, Southborough, MA 01745, fax (508) 480-0002, or email [Managing Editor Melissa Carman at mcarman@massdental.org](mailto:ManagingEditor@massdental.org).

Case Report

Treatment of a Skeletal Class III Malocclusion with Mandibular Asymmetry Using a Single Miniscrew

STEPHEN M. WEISNER, DMD

Dr. Weisner is a diplomate of the American Board of Orthodontists and former instructor in clinical orthodontics in the division of postdoctoral orthodontics at Harvard School of Dental Medicine. He maintains a private orthodontics practice in North Andover.

Editors' Note: This article has been reprinted with permission from the Journal of Clinical Orthodontics. Please visit www.jco-online.com for more information on the Journal of Clinical Orthodontics.

Once a patient's growth is complete, a malocclusion caused by skeletal dysplasia of one or both jaws can be treated in one of two ways. The first option is to correct the skeletal deformity with a combination of orthodontics and orthognathic surgery; the other is to camouflage the malocclusion with orthodontic tooth movement.¹ The severity of the skeletal disharmony is a major factor in the decision, but such issues as the patient's chief complaint and desires, the potential risks and complications of orthognathic surgery, the cost and time involved, and the potential for relapse must also be carefully weighed.

This article describes orthodontic treatment of a patient with a skeletal Class III malocclusion using a single miniscrew.

Diagnosis

A 17-year-old male patient was referred to our office with the chief complaints of "an underbite and crowded lower teeth." He reported that his impacted maxillary and mandibular third molars had been removed within the preceding six months. Clinical examination revealed Class III molar and canine relationships on the left side and Class I relationships on the right (see Figure 1a and Table 1). The patient's mandibular dental midline was deviated to the right of his maxillary dental midline, which coincided with his facial midline. All permanent teeth were present except for the third molars and the mandibular left and right second

Table 1. Cephalometric Data

	African American Norm ^{2,3}	Pre-treatment	Post-treatment
SNA	84.7°	82.5°	83.5°
SNB	79.2°	82.5°	84.5°
ANB	5.5°	0.0°	-1.0°
FMA	30.0°	27.0°	25.0°
GoGn-SN	38.2°	31.0°	29.0°
Occlusal plane-SN	—	14.0°	12.0°
U1-NA	7.4 mm	10.0 mm	10.5 mm
U1-NA	24.1°	22.0°	23.0°
U1-SN	109.0°	104.0°	106.5°
L1-NB	11.4 mm	8.0 mm	6.0 mm
L1-NB	36.7°	25.0°	16.5°
IMPA	100.0°	91.0°	83.5°
U1-L1	113.8°	127.0°	140.0°
Upper lip-E line	—	-2.0 mm	-3.5 mm
Lower lip-E line	—	6.0 mm	3.0 mm

premolars, which were congenitally missing. The mandibular second deciduous molars were still present.

Diagnostic casts demonstrated 3.5 mm of mandibular crowding. The anterior maxilla was slightly narrow. The right canine and lateral incisor were in crossbite with the mandibular right first premolar, canine, and lateral incisor; the maxillary left lateral incisor and mandibular left canine were also in crossbite. The mandibular dental midline was deviated 3.5 mm to the right of the maxillary dental midline.

Radiographic evaluation showed that the roots of the mandibular second deciduous molars were short, but intact. The

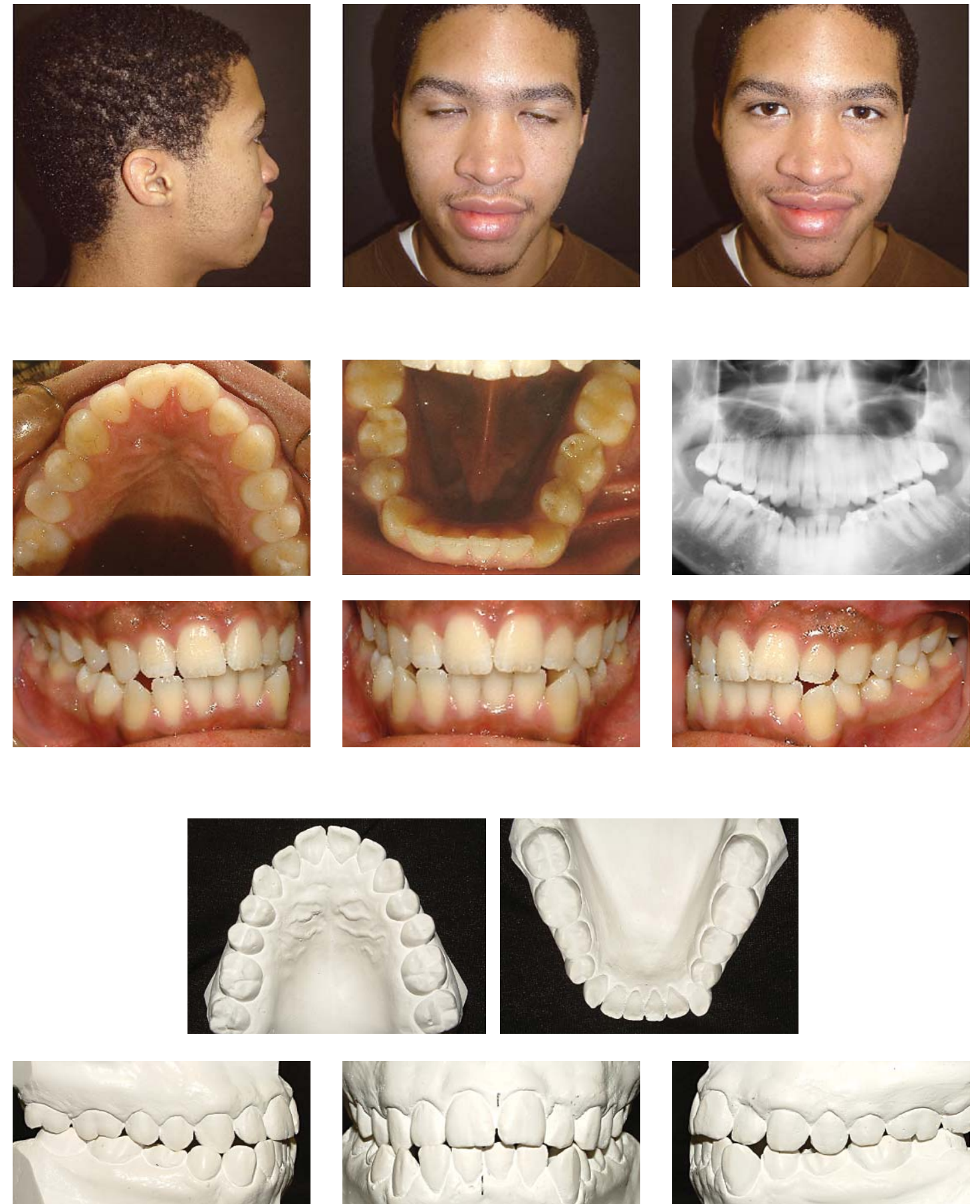


Figure 1a. A 17-year-old male patient with Class III malocclusion on left side, mandibular crowding, midline deviation, and anterior crossbite (continued on page 30).

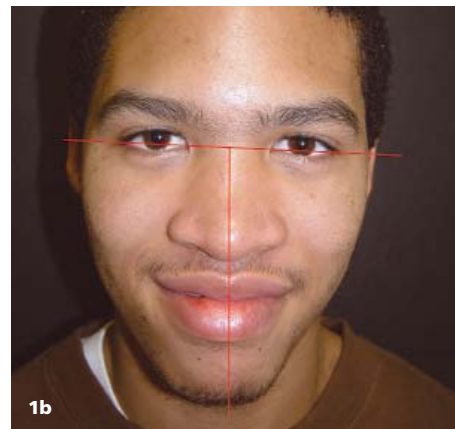
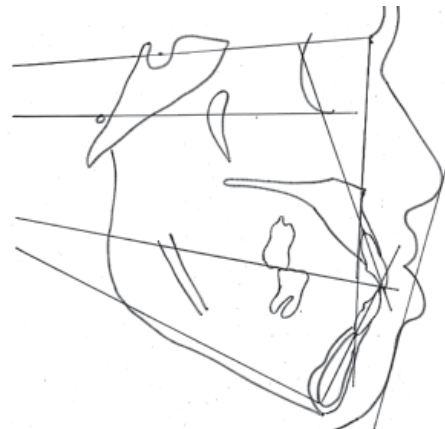
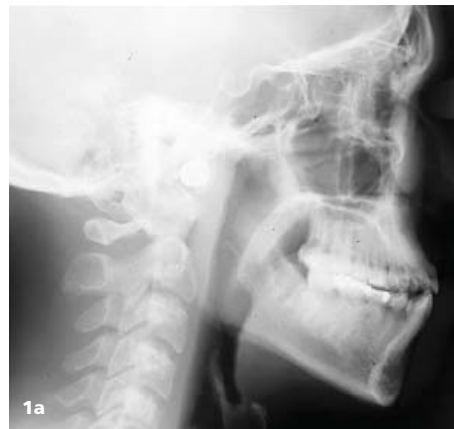

Figure 1a (cont.). A 17-year-old male patient with Class III malocclusion on left side, mandibular crowding, midline deviation, and anterior crossbite. **Figure 1b.** Facial asymmetry evaluated according to Dahan's protocol.⁴

extraction sites of the mandibular third molars had not completely ossified. A cursory evaluation of the frontal digital photograph according to the protocol described by Dahan⁴ demonstrated a mild mandibular deviation to the patient's right (see Figure 1b). Cephalometrically, the patient exhibited a Class III skeletal tendency (ANB = 0°), regardless of whether norms for African-Americans or the general population were used. A hand-wrist radiograph demonstrated that all epiphyses were closed and that the patient's growth was virtually complete (see Figure 2).

Treatment Options

Two surgical procedures were considered: oblique osteotomies and sagittal osteotomies, both of which would involve a mandibular setback and rotation.

Oblique osteotomies would carry a lower risk of alveolar nerve damage, but would require six weeks of intermaxillary fixation. Sagittal osteotomies would allow rigid fixation, but posed a greater risk to the inferior alveolar nerve. Either surgical intervention would correct the mild mandibular asymmetry and the malocclusion, and would also improve the contact between the mandibular left second molar and its maxillary antagonist. Dental implants would eventually be needed after exfoliation of the mandibular second deciduous molars.

The purely orthodontic treatment plan called for removal of the mandibular left second deciduous molar and placement of a temporary anchorage device (TAD) between the mandibular left first and second molars. Treatment goals would be to establish a Class I canine relationship on both sides, bring the mandibular dental midline into alignment with the maxillary midline, correct the anterior crossbite, and address the mandibular crowding. This approach would avoid the need for implant replacement of the congenitally missing left second premolar, but would not correct the skeletal asymmetry or improve the contact of the left second molars. An implant would still be needed after exfoliation of the mandibular right second deciduous molar, and one might also be needed distal to the mandibular left second molar.

An alternative orthodontic approach would involve extraction of the mandibular right second deciduous molar, followed by mesial movement of the mandibular right first and second permanent molars. This could be accomplished with anchorage from a TAD in the extreme mesial portion of the extraction site. Although it would leave the Class I canine relationship on the right side intact, the molar movement would cause a loss of contact between the right second permanent molars, requiring a dental implant distal to the mandibular molar. In essence, this plan would exchange one implant for another; moreover, the additional mechanotherapy might jeopardize the occlusal relationship on the right side.

After careful consideration of the risks and complications of orthognathic surgery, the patient and parents chose the first orthodontic treatment plan. Although it would leave the Class I canine relationship on the right side intact, the molar movement would cause a loss of contact between the right second permanent molars, requiring a dental implant distal to the mandibular molar. In essence, this plan would exchange one implant for another; moreover, the additional mechanotherapy might jeopardize the occlusal relationship on the right side.

After careful consideration of the risks and complications of orthognathic surgery, the patient and parents chose the first orthodontic treatment plan.

Anchorage Evaluation

The mandibular left second deciduous molar had a mesiodistal dimension of 9 mm. Establishing a Class I canine relationship on the left side would require the mandibular left canine to be distal-

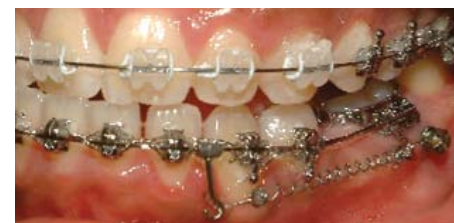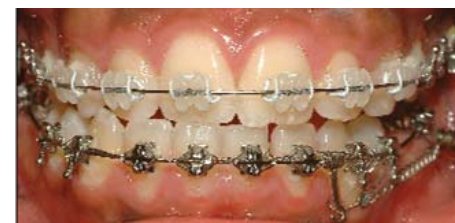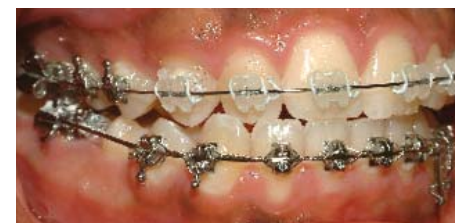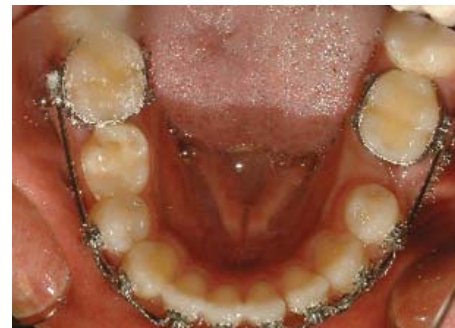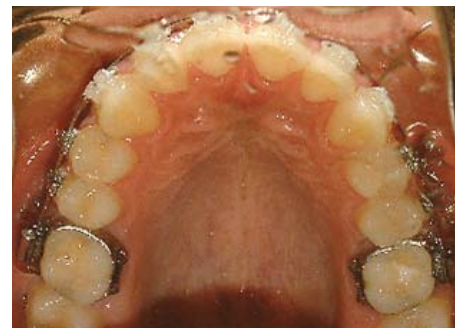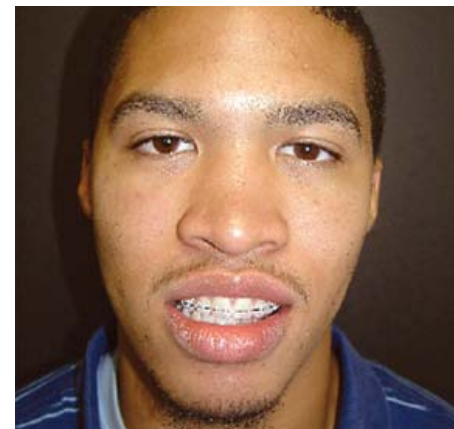
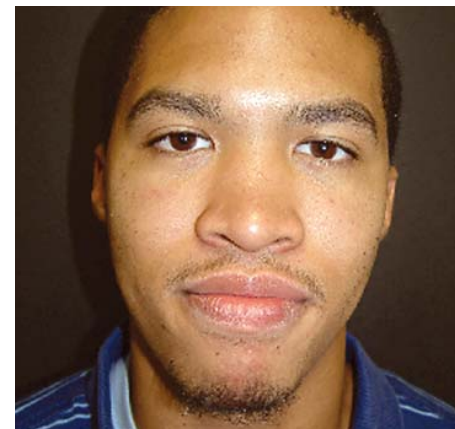


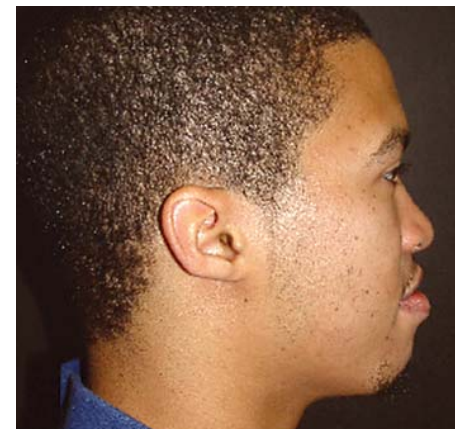Figure 3. Patient after extraction of mandibular left second deciduous molar and placement of miniscrew, with 150g Sentalloy closed-coil spring attached to hook crimped onto .018" round archwire.

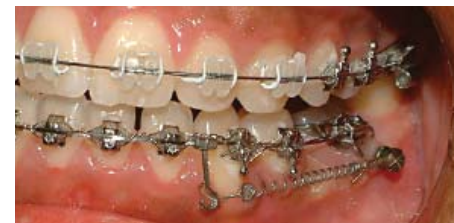
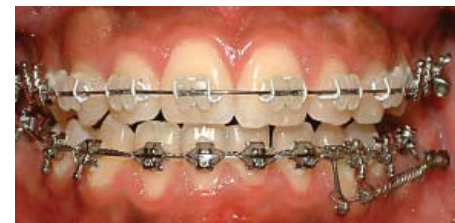
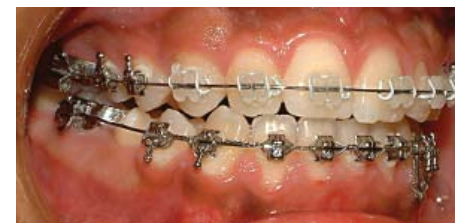Figure 4. Attachment of 200g Sentalloy closed-coil spring six weeks after miniscrew placement.

ized 6.5 mm. Anchorage loss is affected by numerous factors, including the degree of crowding, the type of mechanics, the patient's age, the size of the extraction space, and the overjet.⁵ Creekmore's "rule of thumb" states: "Ordinarily when mandibular second bicuspids [or, in this case, mandibular second deciduous molars] are extracted, you can expect the posterior teeth to come forward about half the extraction site."⁶ Therefore, if the mandibular left second deciduous molar were extracted and conventional

Class I space-closing mechanics used, 4.5 mm of the extraction space would be lost through mesial movement of the mandibular left molars. Additional posterior anchorage loss would result from correcting the mandibular crowding and moving the mandibular midline 3.5 mm to the patient's left. Although a Class III elastic worn on the left side would not tax the anchorage units, its vertical vector would cant the occlusal plane. In addition, the elastic would cause the maxillary midline to shift to the patient's right.

Strategic placement of a miniscrew could avoid this anchorage loss and the undesirable side effects.

Treatment Progress

Brackets were bonded in both arches, and leveling and alignment were carried out with .016" round nickel-titanium archwires. The archform was then developed with .018" stainless steel archwires.

Under local anesthesia, the mandibular left second deciduous molar was removed, and a miniscrew* (8 mm long,

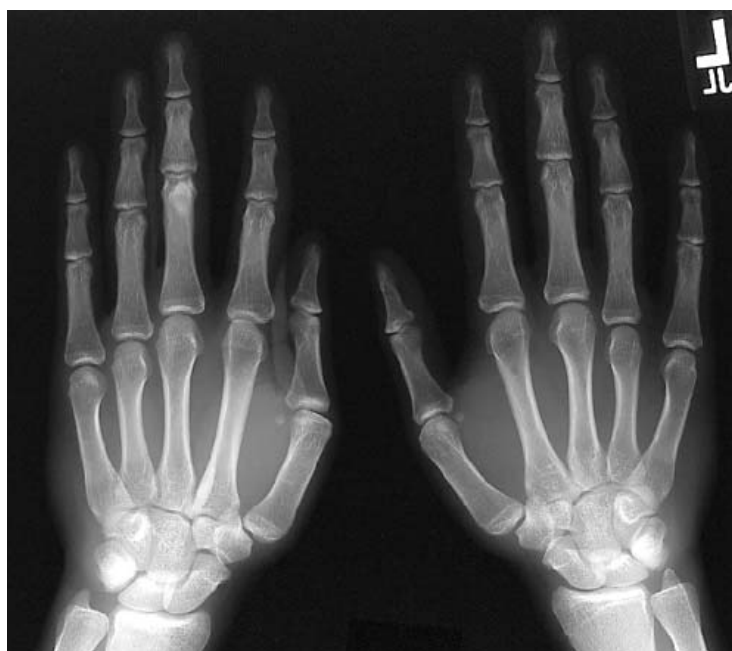

Figure 2. Hand-wrist radiograph indicating closure of epiphyses and completion of growth.

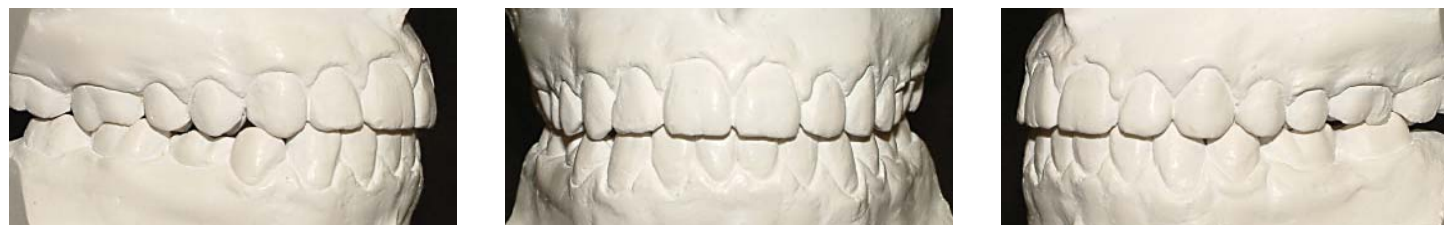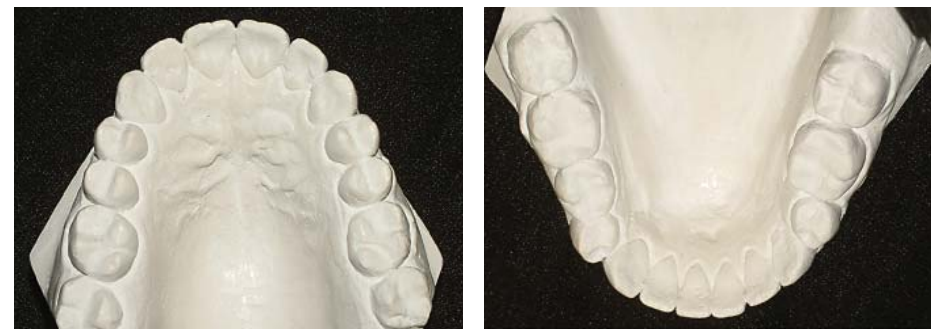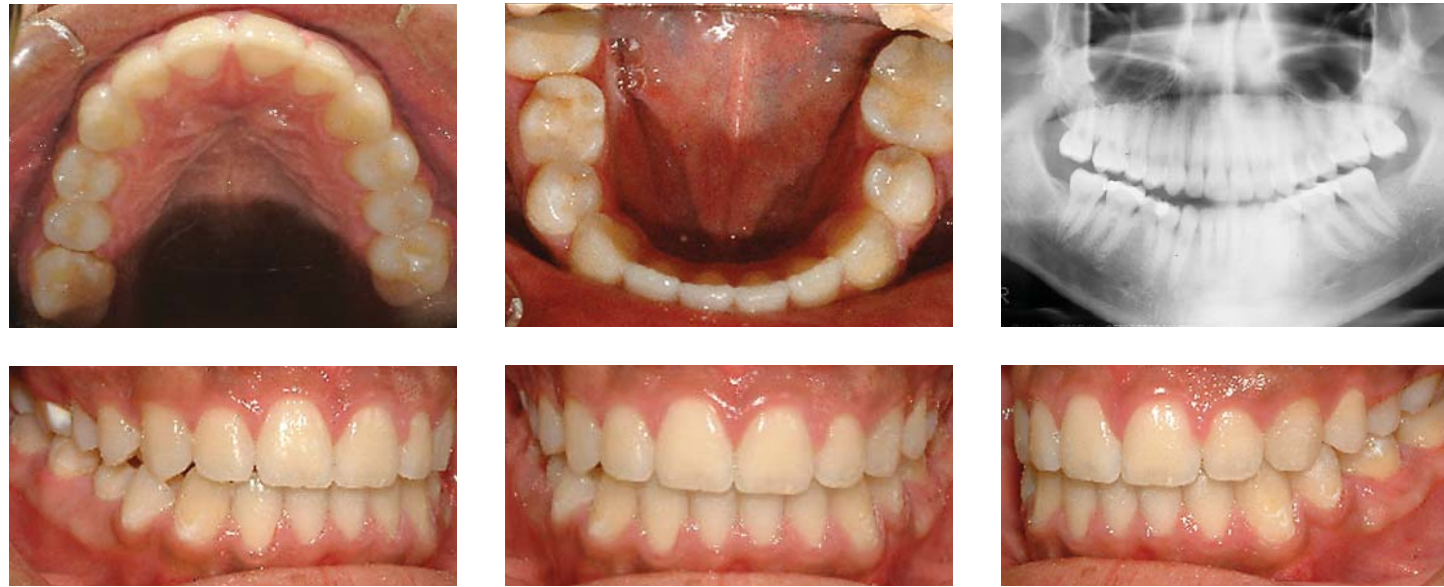
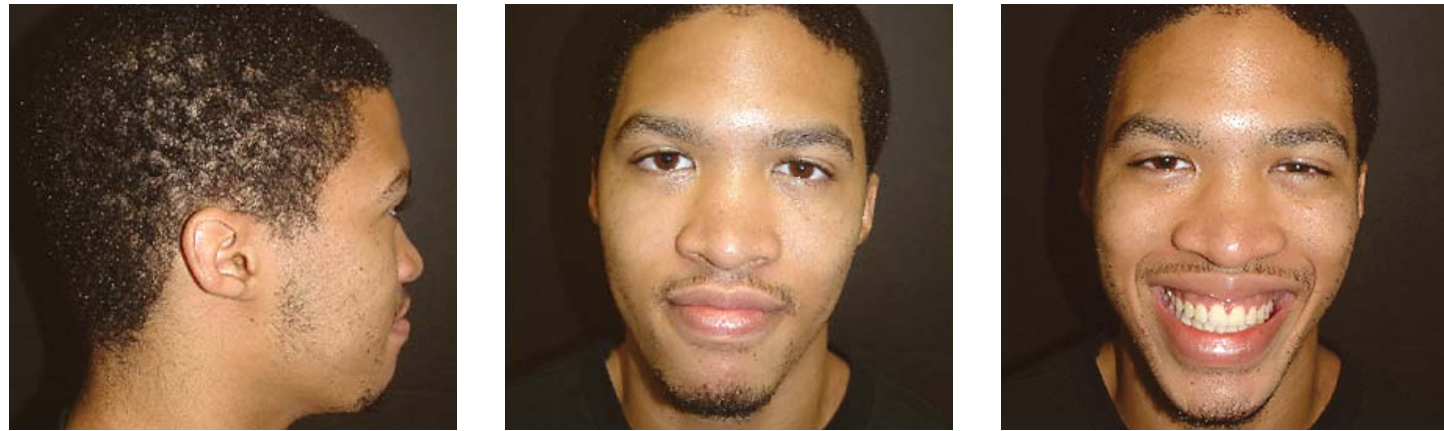


Figure 5a. After 25 months of treatment, Class I canine relationship achieved on left side; mandibular dental midline coincident with maxillary midline (continued on page 33).

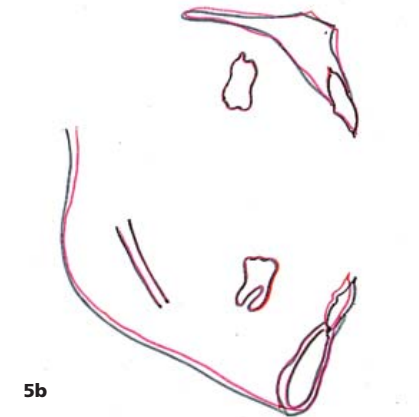
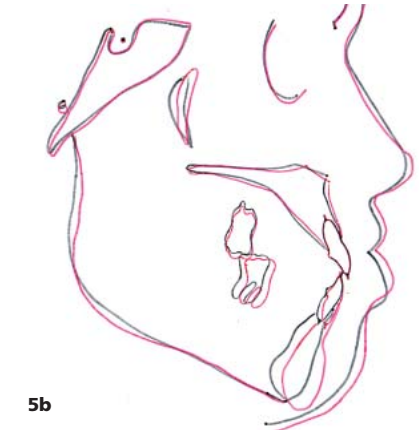
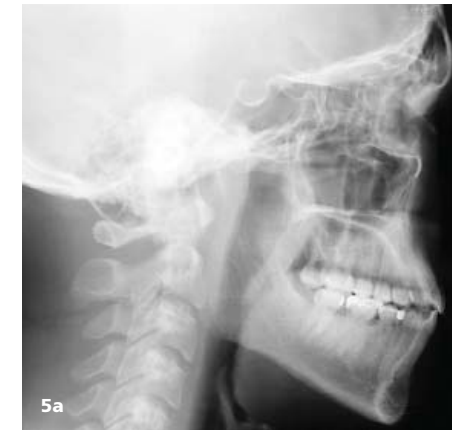


Figure 5a (cont.). After 25 months of treatment, Class I canine relationship achieved on left side; mandibular dental midline coincident with maxillary midline.
Figure 5b. Superimpositions of pre- and posttreatment cephalometric tracings, demonstrating continued Class III growth, retraction of mandibular incisors, and slight mesial movement of mandibular left first molar.

1.5 mm in diameter) was inserted. Placement of a self-drilling screw in the attached gingiva avoided damage to the mucosa and eliminated the need for pilot drilling. The TAD was inserted at a right angle to the buccal cortical bone between the mandibular left first and second molars, close to the center of resistance of the teeth.

A 7 mm crimpable hook** was placed on the archwire between the mandibular left canine and lateral incisor to allow application of a horizontal force vector from the hook to the miniscrew (see Figure 3). Vertical skewing forces were eliminated because the vector was parallel to the occlusal plane. The direction of force through the center of resistance of the teeth allowed bodily movement of the dentition and reduced frictional forces as the archwire moved through the mandibular left molar tube. The right side of the lower archwire was tied back to the mandibular right first molar, and the arch was coligated. The miniscrew was loaded immediately with a relatively light force to facilitate primary stabilization;^{7,8} a 150g Sentalloy*** closed-coil spring was used to apply a constant and long-acting force.

Six weeks later, the mandibular archwire was replaced with an .016" × .022" stainless steel wire, and a 200g Sentalloy closed-coil spring was placed between the miniscrew and the archwire hook (see Figure 4). Correction of the canine and crossbite relationships took eight months. After the Class I canine relationship was established on the left

side, only 1 mm of extraction space remained to be closed with an elastic chain. Cephalometric analysis indicated that additional mandibular growth had occurred in a counterclockwise direction (see Table 1); since the right side remained in a Class I relationship, the mandibular growth continued to be asymmetrical. This not only necessitated more canine and incisal retraction than originally anticipated, but also reduced the contact between the left second molars.

The brackets were debonded after 25 months of treatment, one week before the patient was to return to college (see Figures 5a and 5b). A thermoformed maxillary retainer was fabricated to prevent supereruption of the maxillary left second molar and the maxillary right first and second premolars. When the patient returns home during a break from college, he will be evaluated for a composite buildup of the occlusal surface of the mandibular right second deciduous molar, along with an implant distal to the mandibular left second molar.

Conclusion

Miniscrew anchorage simplified the biomechanics involved in this case and led to a satisfactory outcome without the need for orthognathic surgery. The use of TADs allows the application of force vectors that were previously difficult or impossible to achieve. This enables the clinician to produce the desired dentoalveolar or skeletal changes without detrimental side effects.^{7,9} ■

References

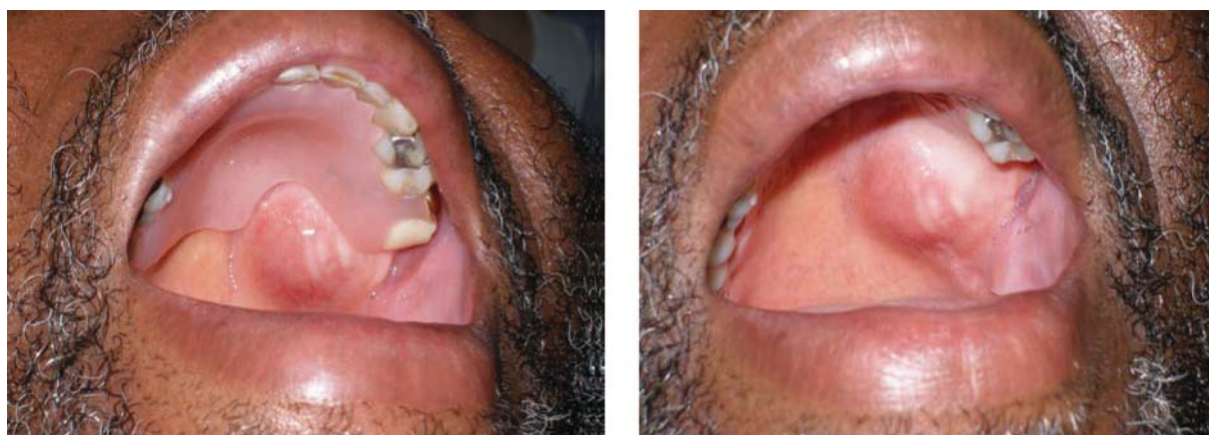1. Turpin DL. Camouflage might not mean compromise. *Am J Orthod.* 2003;123:241.
2. Drummond RA. A determination of cephalometric norms for the Negro race. *Am J Orthod.* 1968;54:670-682.
3. Alexander TL, Hitchcock HP. Cephalometric standards for American Negro children. *Am J Orthod.* 1978;74:298-304.
4. Dahan J. A simple digital procedure to assess facial asymmetry. *Am J Orthod.* 2002;122:110-116.
5. Geron S, Shpack N, Kandos S, Davidovitch M, Vardimon AD. Anchorage loss—a multifactorial response. *Angle Orthod.* 2003;73:730-737.
6. Creekmore TD. Where teeth should be positioned in the face and jaws and how to get them there. *J Clin Orthod.* 1997;31:586-608.
7. Mah J, Bergstrand F. Temporary anchorage devices: a status report. *J Clin Orthod.* 2005;39:132-136.
8. Melsen B, Costa A. Immediate loading of implants used for orthodontic anchorage. *Clin Orthod Res.* 2000;3:23-28.
9. Carano A, Velo S, Leone P, Siciliani G. Clinical applications of the Miniscrew Anchorage System. *J Clin Orthod.* 2005;39:9-24.

* OrthoAnchor is a trademark of KLS Martin (Jacksonville, FL)
** Ortho Organizers (Carlsbad, CA)
*** Registered trademark of GAC International, Inc. (Bohemia, NY)

A Clinico-Pathologic Correlation

MATTHEW R. WIMMER, DMD
RYAN A. ABDOL, DMD
LYNN W. SOLOMON, DDS, MS
WILLIAM C. GILMORE, DMD, MS

Dr. Wimmer is currently in a one-year oral and maxillofacial surgery internship with the St. John Health System/John D. Dingel Detroit V.A. Medical Center; Dr. Abdool maintains a private practice in Quincy; and Dr. Solomon is an associate professor in the department of oral and maxillofacial pathology and Dr. Gilmore is a professor in the department of oral and maxillofacial surgery at Tufts University School of Dental Medicine.



Figures 1a–1b. Clinical photos taken at the time of presentation show views of the lesion with and without the acrylic bent-wire partial denture in place.

History

A 48-year-old African American male was referred to the Oral and Maxillofacial Surgery Clinic at Tufts University School of Dental Medicine for evaluation of an intraoral swelling on the left posterior hard palate. The patient reported that the lesion had been slowly increasing in size for the past eight to nine months. The patient first became aware of the swelling when he noted increasing pain when wearing his maxillary partial denture. His medical history was significant for pharmacologically controlled hypertension. Clinical examination showed a single, pink, dome-shaped nodule, measuring 2.0 cm in diameter, on the left posterior hard palate. The lesion was firm and non-tender on palpation, with a smooth, intact mucosal surface and faint spider-web telangiectasias. Of note is the alteration of the acrylic bent-wire partial denture to accommodate the swelling, in response to the patient's complaint of pain (see Figures 1a–1b).

Differential Diagnosis

- Minor salivary gland tumor
- Mucoepidermoid carcinoma
 - Pleomorphic adenoma
 - Adenoid cystic carcinoma
 - Carcinoma ex pleomorphic adenoma
 - Non-Hodgkin's lymphoma

Biopsy

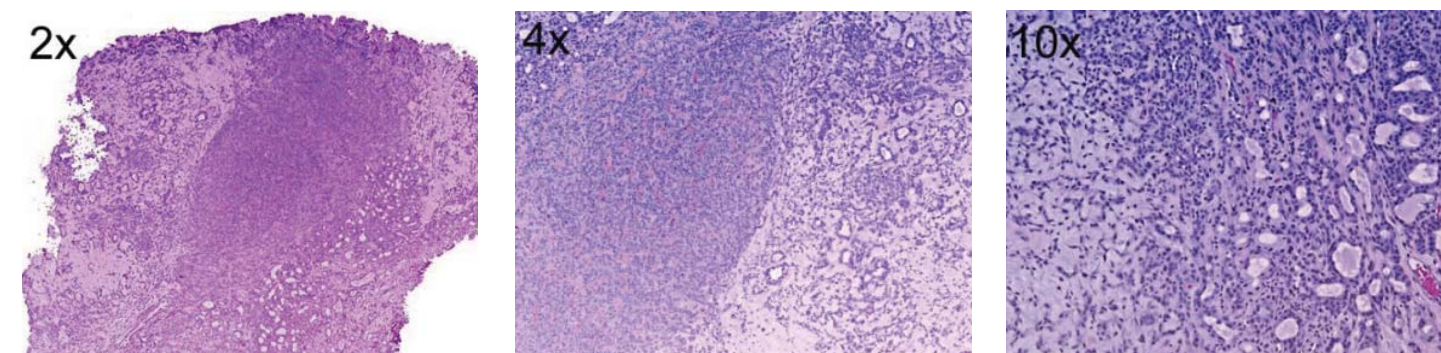
Local anesthesia was obtained and needle aspiration yielded a negative result. An incisional biopsy, down to the periosteum, was performed. The specimen was fixed in formalin and sent for histopathologic evaluation by Tufts Oral and Maxillofacial Pathology Services.

Histopathologic Examination

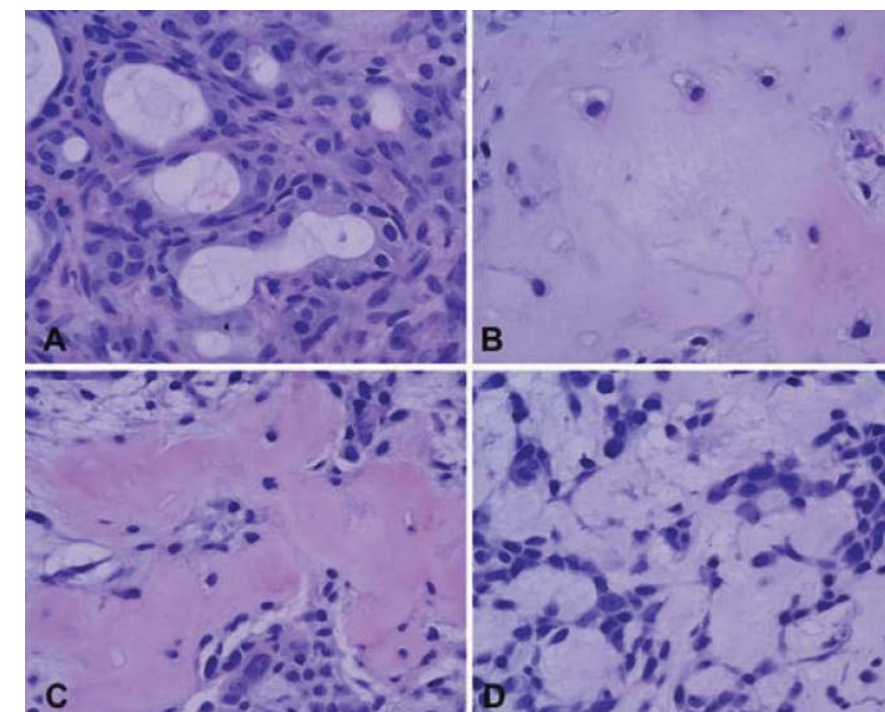
Microscopic examination of tissue sections showed a wedge of palatal mucosa surfaced by stratified squamous epithelium. The fibrous connective tissue stroma was replaced by a proliferation of mucoserous glands and ducts in a myxomatous and chondromatous background. In addition, mild inflammation was noted, as well as scattered lobules of minor salivary glands. The islands, nests, and strands of the neoplastic proliferation extended to the lateral and deep specimen margins (see Figures 2a–2c and 3a–3d).

Diagnosis

Pleomorphic adenoma (PA)



Figures 2a–2c. Low-, medium-, and high-power views demonstrate the architectural diversity of the tumor. Original magnifications of 2x, 4x, and 10x, respectively.



Figures 3a–3d. These high-power photomicrographs demonstrate why the pleomorphic adenoma is also known as a “mixed tumor.” Figure 3a shows an area of ductal differentiation containing a wispy mucoid luminal product. In Figure 3b, a paucicellular area of myxohyaline material resembling chondroid is illustrated. In Figure 3c, deposits of amorphous eosinophilic hyaline separate neoplastic epithelial cells. Figure 3d depicts amorphous basophilic “stromal” material separating narrow, anastomosing epithelial strands. Original magnification of all photomicrographs is 40x.

Discussion

Minor salivary glands are distributed throughout the oral cavity, except for the anterior two-thirds of the tongue, the attached gingiva, and the anterior hard palate.¹ The worldwide annual incidence of salivary gland tumors is 1 in 6.5 cases per 100,000 population; of these, minor glands are involved in 9 to 23 percent of cases.² According to Ellis et al. in their report on 3,355 minor gland tumors, 44 percent were located in the palate, 21 percent in the lips, and 12 percent in the buccal mucosa; 51.3 percent were found to be benign and 48.7 percent were malignant.¹

Clinically, the PA presents as a painless, slow-growing, firm mass. In the palate, PA accounts for 47 percent of the minor salivary gland tumors. The most common location is the posterior lateral hard palate, and it usually does not cross the midline.^{1,4} PA is most common in adults ages 30–50 and has a predilection for females.^{2,4} This tumor is contained in a fibrous capsule,

although in minor gland tumors the capsule may be incomplete. Histologically, PA consists mainly of glandular epithelium and myoepithelial cells in a mesenchyme-like background.^{1,2}

In the original Greek, *pleomorphic* means “many formed.” PA is still commonly known as a “mixed tumor,” thus named because it may contain many histologically different cell types, including ductal, keratinizing squamous, mucous, adipose, and myoepithelial cells. In addition, materials such as mucin, osteoid, hyalinized cartilage, and a tyrosine-rich crystalloid material can be present within isolated areas or widespread throughout the tumor.^{1,2,4} Tyrosine-rich crystals are most common in PAs that occur in African American patients, and have been observed in 21 percent of tumors from this population.^{1,4} The ductal cells appear as normal intercalated ducts whose lumina are lined with a single layer of ductal epithelium. These ducts are in turn

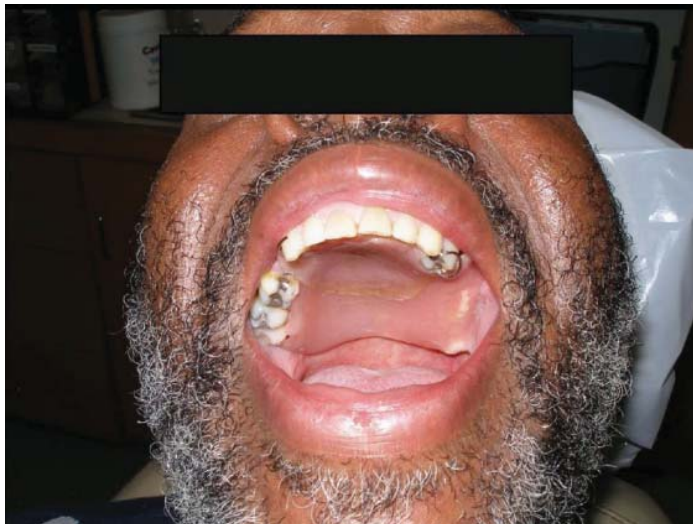
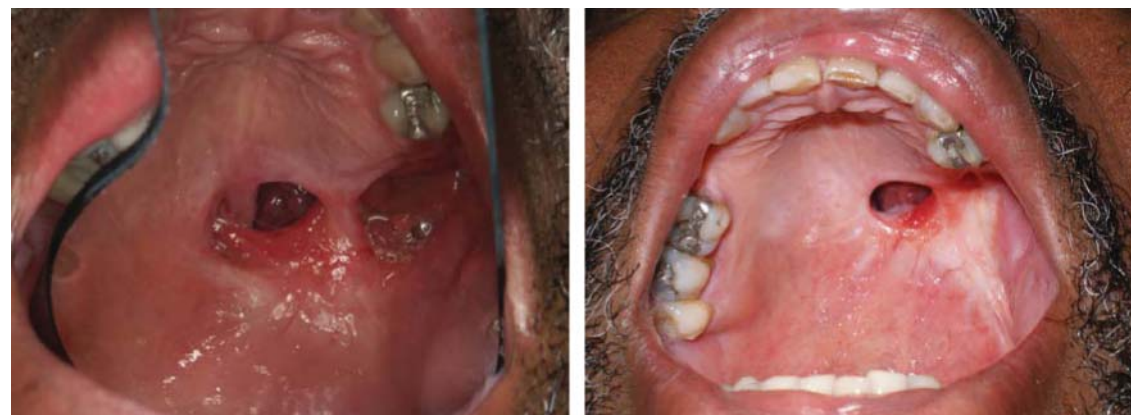
Figure 4. An obturator was fabricated to fill the defect between the hard palate and nasal floor caused by the surgical tumor removal.



Figures 5a–5b. These clinical photos show the postoperative palatal defect that connects the oral cavity with the nasal cavity. Figure 5a was taken using a mirror two months postoperatively. Figure 5b shows a considerable reduction in size of the defect one year postoperatively, although an obturator is still necessary to close off the oral and nasal cavities.

surrounded by myoepithelial cells that often have a layer of mucoid material surrounding them.^{1,2} Myoepithelial cells make up a large portion of pleomorphic adenomas.¹ The tumor epithelium often presents with cells in the form of sheets, nests, or anastomosing cords.

Pleomorphic adenoma is a benign tumor; however, with neglect it can become quite large and may undergo malignant transformation into carcinoma ex pleomorphic adenoma. A clinical sign of transformation is a period of rapid growth of a previously indolent tumor. The treatment of pleomorphic adenoma is surgical excision, making sure to remove the tumor with adequate margins of healthy tissue. With good surgical margins, the tumor has an extremely low propensity for recurrence and often has a 95 percent cure rate.^{1,2}

In the present case, a partial maxillectomy was performed under general anesthesia in an ambulatory surgical setting. The margins of the surgical resection were tumor free. The patient was fitted with an obturator at the time of the surgery (see Figure 4). The procedure was well tolerated and healing was uneventful (see Figures 5a–5b).

Other neoplasms to be considered in the differential diagnosis of a firm, slow-growing nodule of the hard palate include mucoepidermoid carcinoma, adenoid cystic carcinoma, carcinoma ex pleomorphic adenoma, and non-Hodgkin's lymphoma.

Mucoepidermoid carcinoma (MEC) accounts for 10 percent of all major salivary gland tumors and 15–21 percent of all minor salivary gland tumors in the United States.⁴ The most common site for MEC of the minor salivary glands is the hard palate, which is also the second-most-common site overall.^{2,4,5} This lesion is also the second-most-common malignant salivary tumor. MEC has a slight female predilection and is the most common salivary gland neoplasm affecting children.² It affects a wide age group, and patients range from the second to seventh decades of life. MEC presenting in the palate appears as a slow-growing, painless, and sometimes fluctuant swelling, usually without ulceration. The color of the lesion may be blue or reddish, and MEC may demonstrate surface telangiectasia.^{2,4} Histologic examination reveals a lack of encapsulation and a mixture of squamous, intermediate, and mucous cells. The mucous cells have cytoplasm that is “foamy” in appearance. The squamous, or epidermoid, cells have a polygonal shape and contain intercellular bridges and occasionally demonstrate keratinization.^{2,4} Intermediate cells are commonly seen and are thought to differentiate into both mucous and epidermoid cells.² Treatment of mucoepidermoid carcinoma of the minor salivary glands is surgical excision.^{2,4,5}

Adenoid cystic carcinoma (ACC) may occur in any major and minor salivary gland. For the 50 percent occurring in the

minor glands, the palate is the most common site. ACC constitutes 8–15 percent of all palatal salivary tumors.² ACC is most common in the fourth to sixth decades of life and does not have a predilection for either gender.⁴ This malignancy often presents as a slow-growing swelling of the posterior-lateral palate.^{2,5} Histologically, ACC can present in four forms: cribriform, tubular, solid, or a combination of the three. The cribriform pattern is the most common and well-recognized form with a “Swiss cheese” appearance. This unique appearance stems from islands of basaloid epithelial cells surrounded by many cylindrical spaces, which contain either a basophilic mucoid material or an eosinophilic hyalinized substance. The tubular pattern appears as many small ducts in a hyalinized stroma, and the solid form contains large sheets or islands of cells that have a low propensity to form ducts.^{2,5} Because ACC is prone to local recurrence in up to 32 percent of cases, wide surgical excision is recommended.²

Carcinoma ex pleomorphic adenoma is the most common form of malignant mixed tumor. The tumor arises from the malignant transformation of a neglected pleomorphic adenoma. The chance of malignant transformation is low (approximately 5 percent of all PA cases) but increases with the patient's age and duration of the tumor.^{1,2} Carcinoma ex pleomorphic adenoma has peak prevalence from ages 60 to 80, approximately 15 years later than diagnosis of benign PA. Two-thirds of the cases reported in minor salivary glands arise in the palate. A clinical sign of malignant transformation is recent rapid growth or pain in a mass that has been present for many years. Histological features of carcinoma ex pleomorphic adenoma show the presence of cellular pleomorphism and abnormal mitotic figures in conjunction with evidence of benign PA. Treatment for carcinoma ex pleomorphic adenoma is wide surgical excision with local lymph node dissection, if nodal metastases are present, and adjunctive radiation therapy.²

Approximately 58,000 cases of non-Hodgkin's lymphoma occur annually in the United States, with a mortality rate of approximately 33 percent.² Lymphoma is most common in patients with underlying immune system conditions, such as AIDS, organ transplants, or various autoimmune diseases.² Non-Hodgkin's lymphoma usually presents in lymph nodes, but in the United States, 20–40 percent of cases develop in extranodal sites. In the oral cavity, non-Hodgkin's lymphoma presents in soft tissues as a painless swelling with or

without ulceration. The most common locations are the posterior hard palate, buccal vestibular areas, or gingiva.^{2,3} It is important to note that at the time of intraoral presentation of non-Hodgkin's lymphoma, there is often evidence of disease in distant sites. However, an intraoral swelling may be the presenting sign of disease with no other signs elsewhere in the body, although disseminated disease may develop in the future.⁴ Histopathologic studies of non-Hodgkin's lymphoma show minor salivary glands invaded by lymphocytes that can be monomorphic, pleomorphic, and both well or poorly differentiated.^{2,4} Treatment consists of radiation and adjuvant chemotherapy. Palatal lesions, in particular, have been shown to resolve with 8–10 Gy of radiation.⁴

Conclusion

With early detection, pleomorphic adenoma can be removed with minimal consequence while the tumor is still small. Unfortunately, in this patient's case the tumor had reached considerable size and its surgical removal led to a fistula in the hard palate, creating a communication between the oral and nasal cavities. This case demonstrates the importance of regular oral soft-tissue examinations by dentists and the need to have suspicious oral lesions surgically biopsied as soon as possible. ■

References

1. Ellis GL, Auclair PL, Gnepp DR. Surgical pathology of the salivary glands. Philadelphia (PA): W.B. Saunders; 1991.
2. Neville BW, Damm DD, Allen CM, Bouquot JE. Oral and maxillofacial pathology. 3rd ed. Philadelphia (PA): W.B. Saunders; 2009.
3. Kolokotronis A, Konstantinou N, Christakis I, Papadimitriou P, Matakis A, Zaraboukas T, Antoniadis D. Localized B-cell non-Hodgkin's lymphoma of oral cavity and maxillofacial region: a clinical study. *Oral Surg Oral Med Oral Pathol Oral Radiol Endodont.* 2005;99:303-310.
4. Eversole LR. Clinical outline of oral pathology: diagnosis and treatment. Philadelphia (PA): Lea & Febiger; 1992.
5. Yih WY, Kratochvil FJ, Stewart JCB. Intraoral minor salivary gland neoplasms: review of 213 cases. *J Oral Maxillofac Surg.* 2005;63:805-810.
6. Rapidis AD, Givalos N, Gakiopoulou H, Stavrianos SD, Faratzis G, Lagogiannis GA, Katsilieris I, Patsouris E. Mucoepidermoid carcinoma of the salivary glands. Review of the literature and clinicopathological analysis of 18 patients. *Oral Oncol.* 2007;43:130-136.
7. Wood NK, Goaz PW. Differential diagnosis of oral and maxillofacial lesions. 5th ed. New York (NY): Mosby; 1997. p. 149-153.
8. Triantafyllidou K, Dimitrakopoulos J, Iordanidis F, Koufogiannis D. Management of adenoid cystic carcinoma of minor salivary glands. *J Oral Maxillofac Surg.* 2006;64:1114-1120.

DENTAL CAREER NETWORK

Looking for a Job? Have a Position to Fill?

The Massachusetts Dental Society and Boston University Henry M. Goldman School of Dental Medicine have joined forces to offer the Dental Career Network, New England's most comprehensive online job database for dental professionals.

Open to all dental personnel, the Dental Career Network is free for job seekers and available at minimal cost to employers.

www.dentalcareernetwork.com

Take Advantage of the MDS Discount

Based on the combined buying power of its membership, the MDS has secured a variety of business discounts for its members.

A full list of MDS business services is available at www.massdental.org/atyourservice.



Incidental Findings on Dental Radiographs: Stafne Bone Defect

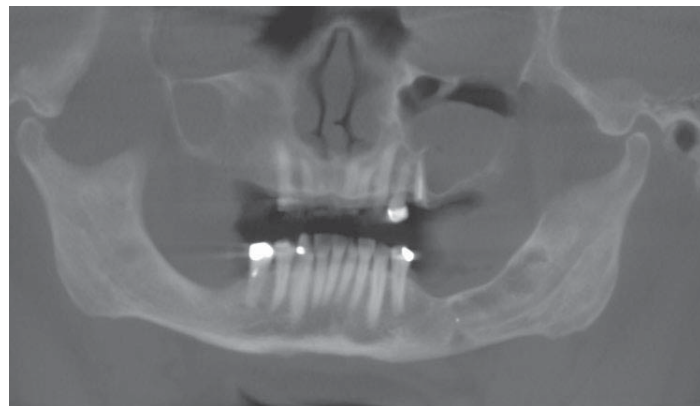


Figure 1a. Panoramic view generated from the CBCT data shows the submandibular gland depression in the left mandible.

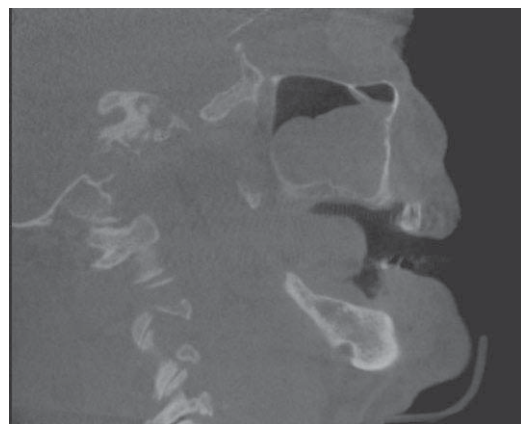


Figure 1b. CBCT sagittal view shows the submandibular gland depression in the left mandible.

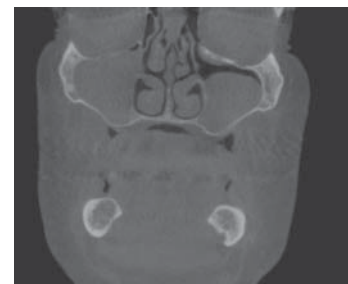

Figure 1c. CBCT coronal view shows the submandibular gland depression in the left mandible.

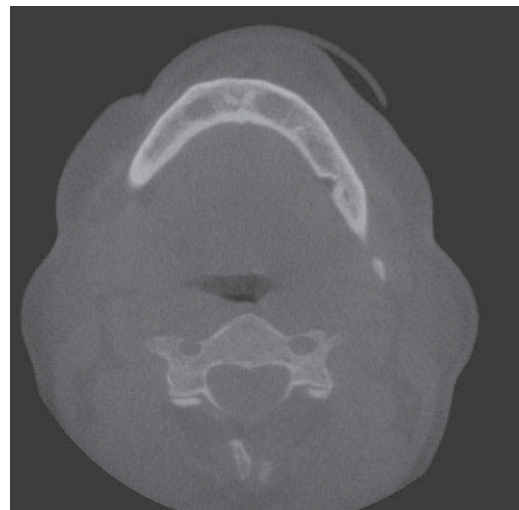


Figure 1d. CBCT axial view shows the submandibular gland depression in the left mandible.

Developmental salivary gland depressions and Stafne bone defects or cysts have been incidental findings in many panoramic radiographs and sometimes in periapical radiographs. The average incidence is reported to be between 0.1 and 1.8 percent in the general population.^{1,2}

Many believe that these depressions form to accommodate the submandibular salivary gland tissue and, hence, are considered developmental in origin. In 1981, a study by Chen and Ohba found the content of these developmental cavities to be mostly salivary gland tissue and sometimes fatty or lymphatic tissue and muscle.¹ Very rarely, benign tumors like pleomorphic adenoma and hemolymphangioma have been found. There have also been cases where these depressions were empty cavities.¹

The typical radiographic presentation is a defined corticated radiolucency along the inferior cortex of the mandible below the inferior alveolar nerve (IAN) canal. This radiolucency is usually located in the posterior mandible in the second molar to the mandibular angle region. Developmental salivary gland depressions are usually not treated. The rationale is that after a period of five to eight years, the lesions achieve their mature presentation and remain stable. The destruction of well-defined cortex of the defect may be indicative of a neoplasm and would require intervention.

Most of the cases described in literature are based on panoramic radiographs. Two cases with radiographic presentations of developmental salivary gland depressions in 3-D cone-beam computed tomography (CBCT) are presented here.

ARUNA RAMESH, BDS, DMD, MS
TARUNJEET PABLA, BDS, MS

Dr. Ramesh is head and associate professor for the department of general dentistry in the division of oral and maxillofacial radiology at Tufts University School of Dental Medicine. Dr. Pabla is an oral and maxillofacial radiologist. They are both diplomates of the American Board of Oral and Maxillofacial Radiology.

Case Report 1

A CBCT scan was obtained in a 70-year-old male for treatment planning for dental implants. The CBCT scan revealed a well-defined radiolucency with dense corticated margin in the lingual aspect of left mandibular molar region. The lesion was located inferior to the IAN canal, and the lesion measured 5.77 mm x 4.02 mm x 5.41 mm. The radiographic diagnosis for the lesion was Stafne bone defect. In the absence of any signs and symptoms, no further evaluation was suggested. The radiographic appearance of the lesion in multiple planes is shown in Figures 1a–1d.

Case Report 2

A CBCT scan on a 68-year-old female revealed a well-defined corticated left mandibular radiolucency measuring 10.5 mm x 11.29 mm x 12.5 mm in size. The lesion was causing interruption in the lingual mandibular cortex and was located inferior to the IAN canal. The radiographic diagnosis was Stafne bone defect, or developmental salivary gland depression. No intervention was recommended. The radiographic appearance of the lesion in multiple planes is shown in Figures 2a–2c. ■

References

1. Chen CY, Ohba T. An analysis of radiological findings of Stafne's idiopathic bone cavity. *Dentomaxillofac Radiol.* 1981;10:81.
2. D'Eramo EM, Poidmore SJ. Developmental submandibular gland defect of the mandible: review of the literature and report of a case. *Oral Surg Oral Med Oral Pathol.* 1986;61:213.

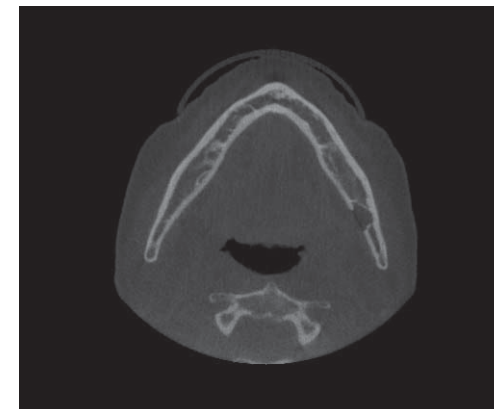


Figure 2a. CBCT axial view shows the submandibular gland depression in the lingual aspect of the left mandible.

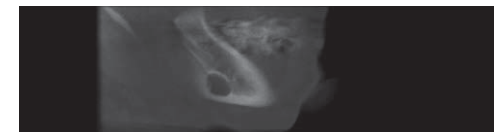


Figure 2b. CBCT sagittal view shows the submandibular gland depression in the left mandible inferior to the IAN canal.

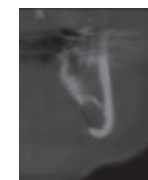

Figure 2c. CBCT cross-sectional view shows the submandibular gland depression in the left mandible.

*A new name and a new look...
but the same great service.*

Dickerman
Dental Prosthetics

Implant Systems

- All implant systems
- Authorized NobelGuide™ Dental Laboratory
- Radiographic and surgical guides
- Distributor for 3i®, AstraTech, Nobel Biocare™ and Straumann implant components

Removable Prosthetics

- Ivoclar® injected complete dentures
- Titanium cast partial frameworks
- Night guards – hard/soft laminated
- Denture relines and laser-welded repairs

Conventional Services

- Full-mouth reconstruction
- Precision attachment combination restorations
- Maryland and Monodont bridges
- Temporaries – heat cured – cast reinforced
- Full gold crowns, inlays and onlays

Ceramic Systems

- CAD/CAM technologies
- Major “all-ceramic systems”
- Diagnostic waxups for full arch treatment planning

Cresco™ Precision
Implant Frameworks
“Precision Laboratory”

Call today for your free “new doctor” kit
781.828.2808

Quality ■ Service ■ Expertise

Dickerman
Dental Prosthetics

76 Pond St. ■ P.O. Box 355 ■ Sharon, MA 02067
781.828.2808 ■ www.dickermantdental.com



PATHOLOGY SNAPSHOT

VIKKI NOONAN, DMD, DMSC
SADRU KABANI, DMD, MS

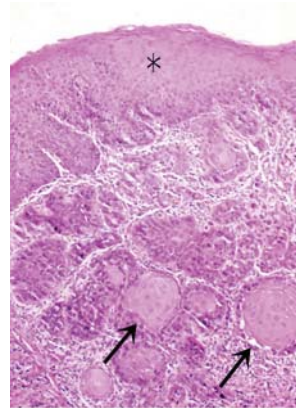
Drs. Noonan and Kabani are oral and maxillofacial pathologists in the department of oral pathology at Harvard Vanguard Medical Associates.

GINGIVAL MALIGNANCY

MALIGNANT LESIONS INVOLVING THE GINGIVA ARE UNCOMMON; however, when such lesions occur, the clinical appearance often resembles commonly encountered inflammatory lesions such as focal reactive gingival hyperplasia or endoperiodontic lesions.¹ Although metastatic disease may involve the gingival soft tissues, in most instances gingival malignancy represents primary squamous cell carcinoma. Approximately 10 to 25 percent of all oral squamous cell carcinomas involve the gingival, and the mandibular gingiva or alveolar ridge is most frequently affected.^{2,3}

Equally found to involve both the dentate gingiva and the edentulous alveolar ridge,⁴ the intimate relationship between the gingival mucosa and underlying alveolar bone may explain the high propensity of bony invasion at the time of diagnosis.⁵ Common clinical presentations for gingival malignancy include evidence of tooth mobility with a radiographic appearance that mimics localized periodontitis or a poorly healing extraction socket.

While the condition typically affects adults, it is important to note that squamous cell carcinoma involving the gingival tissues has been reported with some frequency in young patients.^{5,6} In instances of suspected inflammatory gingival lesions that are unresponsive to conventional therapy, a high index of suspicion for malignancy should exist. A thorough examination as well as a biopsy with submission of lesional tissue for histopathologic evaluation is requisite for ensuring timely diagnosis and management. ■



Low-power view of H&E-stained section shows a well-differentiated squamous cell carcinoma. The asterisk represents surface mucosa, while arrows indicate invasive tumor islands.

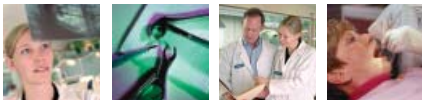References

1. Heller AN, Klein A, Barocas A. Squamous cell carcinoma of the gingiva presenting as an endoperiodontic lesion. *J Periodontol.* 1991;62(9):573-575.
2. Yoon TY, Bhattacharyya I, Katz J, Towle JH, Islam MN. Squamous cell carcinoma of the gingiva presenting as localized periodontal disease. *Quintessence Int.* 2007;38(2):97-102.
3. Makridis SD, Mellado JR, Freedman AL, Salkin LM, Stein MD, Leal D, Miller AS. Squamous cell carcinoma of gingiva and edentulous alveolar ridge: a clinico-pathologic study. *Int J Periodontics Restorative Dent.* 1998;18(3):292-298.
4. Barasch A, Gofa A, Krutchkoff DJ, Disenbert E. Squamous cell carcinoma of the gingiva. A case series analysis. *Oral Surg Oral Med Oral Pathol Oral Radiol Endod.* 1995;80(2):183-187.
5. Bill TJ, Reddy VR, Ries KL, Gampper TH, Hoard MA. Adolescent gingival squamous cell carcinoma; report of a case and review of the literature. *Oral Surg Oral Med Oral Pathol Oral Radiol Endod.* 2001;91(5):682-685.
6. Alsharif MJ, Jiang WA, He S, Zhao Y, Shan Z, Chen X. Gingival squamous cell carcinoma in young patients: report of a case and review of the literature. *Oral Surg Oral Med Oral Pathol Oral Radiol Endod.* 2009;107(5):696-700.

JOURNAL Archives Available Online

Looking for an article you saw in a past issue of the JOURNAL OF THE MASSACHUSETTS DENTAL SOCIETY? All issues of the JOURNAL from the last several years are archived on the MDS Web site and available 24/7 to all MDS members. Please visit www.massdental.org/publications/journal and click on Past Issues. Please note that you will need to log in with your MDS member ID to access the JOURNAL online.





CLINICAL CASE STUDY

DAVID LEADER, DMD

Dr. Leader is assistant clinical professor at Tufts University School of Dental Medicine. He maintains a private practice in Malden.

BUCCAL OBJECT RULE

A 47-YEAR-OLD MALE PATIENT PRESENTED WITH AN INTERESTING lesion, which is easily visible radiographically but is not apparent on visual inspection. Thorough radiographic interpretation is an essential component of diagnosis in dentistry, and the buccal object rule is an important tool of such interpretation. Dentists use the buccal object rule to determine the location of restorations, lesions, and objects in relation to the teeth. The buccal object rule also has an important application in victim identification.

Figure 1 is a periapical radiograph that reveals a radiopacity that appears lodged in the maxillary alveolus, projecting through the masticatory mucosa in the area of the distal root of the missing tooth #2. Based on the information in this image alone, the differential diagnosis includes retained root of #2, odontoma, or a supernumerary tooth. Figure 2, from the same full-mouth survey, includes the hamular notch. Film placement for this image is more distal than that of the first. Note that in Figure 2, the radiopacity is superimposed over the distal of the first molar.

The acronym that radiologists use to teach the buccal object rule is Same Lingual Opposite Buccal (SLOB). The opacity is more mesial in the image that is more distal. Therefore, the unidentified opacity is buccal to tooth #3.

Visual inspection of the area did not reveal the opacity projecting from the buccal surface of the alveolus as expected. Digital inspection of the area had the same finding. Bidigital

examination of the parotid gland revealed a firm inclusion about 1 cm distal to Stinson's duct. Figure 3 is a radiograph of the area taken with a film placed buccal to the teeth. This image revealed that the radiopacity is in the soft tissue of the cheek.

Further discussion with the patient did not reveal any symptomatology that one may expect with a sialolith. However, the patient related an interesting story. Thirty years ago, the patient's father lifted weights for exercise. To support his barbells, he hung a series of chains and sharp hooks from the basement rafters. As a young teenager, the patient suffered injury when a hook accidentally stabbed through his cheek in that same area. The correct differential diagnosis based on history, examination, and radiology includes sialolith, phlebolith, calcified lymph node, and calcified scar;¹ none of the possibilities are life-threatening or dangerous. Without symptoms, this calcification, deep in the parotid gland, does not require treatment. ■

Reference

1. Carter, LC. Soft tissue calcification and ossification. In: White SC, Pharoah MJ. Oral radiology: principles and interpretation. St. Louis (MO): Mosby; 2004. p. 576-596.

Acknowledgment

The author wishes to thank Dr. Lynn Solomon of the department of oral pathology at Tufts University School of Dental Medicine for assistance in researching this article.

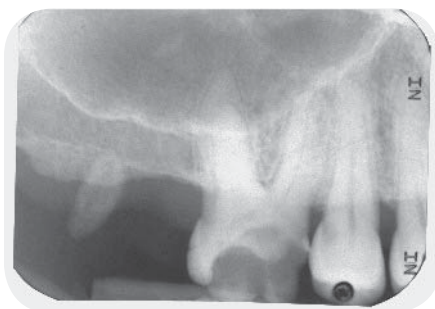

Figure 1. Periapical radiograph reveals a radiopacity that appears lodged in the maxillary alveolus.

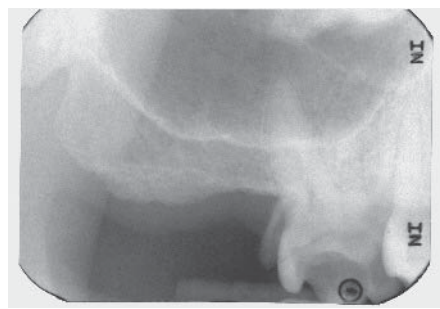


Figure 2. From the same full-mouth survey as Figure 1, this radiograph includes the hamular notch. Note that the radiopacity is superimposed over the distal of the first molar.

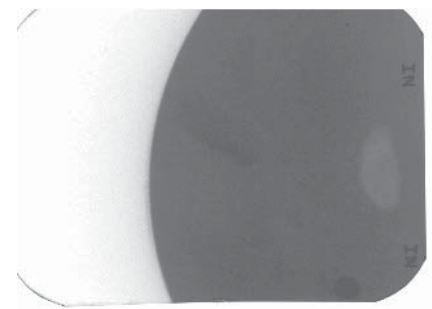



Figure 3. Radiograph taken with a film placed buccal to the teeth reveals that the radiopacity is in the soft tissue of the cheek.

About Clinical Case Study

A Clinical Case Study is defined as a written and visual assessment of a clinical case wherein the author presents before-and-after radiographs and/or photographs as a means to discuss the diagnosis, treatment plan, and actual treatment of a particular situation. The purpose of this study is to encourage JOURNAL readers to contribute a clinical response to the cases presented.

Please address your correspondence to Clinical Case Study, JOURNAL OF THE MASSACHUSETTS DENTAL SOCIETY, Two Willow Street, Suite 200, Southborough, MA 01745. Include your name, address, and phone number or email address so that we may contact you for follow-up. Responses may be published in a future issue of the JOURNAL.



NORMAN BECKER, DDS, EDITOR EMERITUS

Osseointegration: On Continuing Synergies in Surgery, Prosthodontics, and Biomaterials

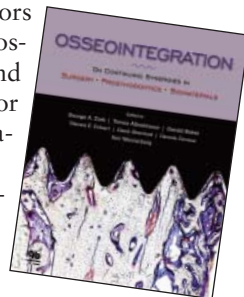
GEORGE A. ZARB, TOMAS ALBREKTSSON, GERALD BAKER, STEVEN E. ECKERT, CLARK STANFORD, DENNIS P. TARNOW, ANN WENNERBERG (EDITORS)

Quintessence Publishing

In an almost novel-like textbook, the editors have gathered many of the pioneers in osseointegration to cover this field of study and clinical use. The text prepares the readers for the past, present, and future of osseointegration in clinical practice.

It was fun reviewing this text. A paragraph in the first chapter sets the tone for the book and indicates how un-textlike the editors are in approaching this book: "This first chapter employs the metaphor to reflect the editors' perception of where we have been and where we are currently, in the context of osseointegration's impact on the management of partial and complete edentulism. Subsequent chapters sum up our convictions as to how far we have come and speculate on where we are heading. We welcome readers to join us in the journey. We promise prudent speed and a more than cursory interpretative glance at the panorama we travel through."

Writing like this made for an enjoyable and informative read.




Wheeler's Dental Anatomy, Physiology, and Occlusion—Ninth Edition

STANLEY J. NELSON, MAJOR M. ASH JR. (EDITORS)

Saunders Elsevier

The ninth edition of this text not only continues with the subject matter and basic information of the previous editions, but the editors have added new features, such as colorization of previously black-and-white illustrations, an expanded and updated section on Forensic Odontology, and the inclusion of "flash cards" that can be used as quick study guides. Additionally, this edition includes "help sites" for faculty and students, a collection of 300 test questions, and an ancillary DVD that features 3-D animation, electronic flash cards, labeling exercises, and a virtual reality tooth identification quiz. The editors use DVD icons in the text margins to point readers to the appropriate sections of the DVD, which may be used as an interactive simulation and learning aid.

Even without the bells and whistles of the DVD, the text itself is a good teaching tool. It is well-organized and uses photographs, figures, and attractive design to maintain reader interest. ■



Guidelines for Adhesive Dentistry—The Key to Success

FRANCESCO MANGANI, ANGELO PUTIGNANO, ANTONIO CERUTTI (EDITORS)

Quintessence Publishing



With the goal of simplifying teaching methods and facilitating the education of students and colleagues, the editors have prepared more of a multimedia presentation in the form of a textbook to be used in conjunction with a DVD.

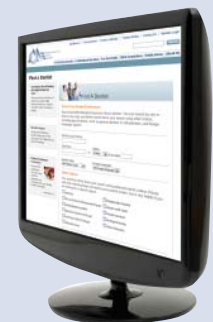Studying seems to become more fun through the course of the text, even if more effort may be needed to play the accompanying DVD. However, in this text, the authors use great photographs (with an almost 3-D appearance) to


emphasize the teaching points. It is a most attractive, colorful, and well-designed text that could fit in many art libraries.

I enjoyed studying the teaching goals of the authors.

MDS Roster Available Online

Do you need to find a colleague's address, office phone, or email address? Use the Find a Member function on the MDS Web site at www.massdental.org/find-a-dentist. You can find members by last name, specialty, or city/town, and the listings are updated daily so you are sure to have the most recent information. Log in and you can also access members' email addresses. Log in to the Web site today at www.massdental.org/login.





DENTAL EDUCATION

MELISSA CARMAN, MANAGING EDITOR

Highlighting key events taking place in dental education in Massachusetts.



Forsyth Institute

The Forsyth Institute has found a new home. In early August, Forsyth signed a long-term lease for a research facility located at 245 First Street in Cambridge. Forsyth is leasing 73,317 square feet to accommodate its state-of-the-art laboratories, a new research clinic, meeting spaces, and administrative offices. In 2007, Forsyth sold its present building at 140 The Fenway in Boston to the Museum of Fine Arts, and remained there as a tenant while completing its search for a permanent location.

Despite its relocation, the organization will maintain a strong commitment to the city of Boston through its community programs, including

ForsythKids, an oral health program for at-risk children that provides dental care at elementary schools and at Boston's Camp Harbor View, and the Educational Outreach Program, which offers paid summer science internships to Boston Public School children.

"We are very excited about our new location, which will enable Forsyth to establish additional collaborations and thrive into its second century," says Dr. Philip Stashenko, Forsyth president and CEO. The institute will celebrate its centennial in its new headquarters in 2010.

In June, three Forsyth Institute scientists were among the first in the country to receive stimulus funding for their research from the National Institutes of Health through the American Recovery and Reinvestment Act of 2009. Drs. Nikos Soukos, Floyd Dewhirst, and John Bartlett received funds totaling \$1,881,788 to help develop potential therapies for oral diseases that cause pain, financial hardship, and long-term systemic health problems for millions of Americans. In addition, these grants from the National Institute of Dental and Craniofacial Research will help sustain laboratory positions and create new jobs.

Dr. Soukos's project, "Nanoparticle-based Antimicrobial Photochemotherapy in Biofilms," aims to develop a clinically appropriate way to enhance the penetration and effectiveness of photoactive compounds into human dental plaque by encapsulating them in biodegradable and biocompatible polymeric nanoparticles. When combined with exposure to visible light, this leads to the killing of disease-causing bacteria, in particular those that are responsible for periodontitis.

Dr. Dewhirst received a two-year grant for his work, "A Foundation for the Oral Microbiome and Metagenome." This

genome sequencing research will foster a greater understanding of the several hundred bacteria that live in the human oral cavity and can cause tooth decay, periodontal disease, and infections elsewhere in the body.

Dr. Bartlett's two-year grant was for his project, "The Role of ER-stress and pH in Fluorosis." The project's goal is to define the role of endoplasmic reticulum (ER) stress responses in dental fluorosis, a condition that results in discolored and/or pitted teeth due to overexposure to fluoride. This work will identify the genes and molecular pathways that respond to fluoride exposure.

Tufts University

Tofigh Raayi, DMD, MScD, was recently named president of the Tufts University Dental Alumni Association for 2009–2010. A past recipient of the Volunteer Hero recognition from the JOURNAL OF THE MASSACHUSETTS DENTAL SOCIETY and past chair of the East Middlesex Dental Society, Dr. Raayi has previously served as president of the American Association of Women Dentists and the Women's Dental Society of Massachusetts, as well as the American Academy of Dental Science.




Michael A. Kahn, DDS, was installed as vice president of the American Academy of Oral and Maxillofacial Pathology on May 19, 2009, during the organization's annual meeting in Montreal. Dr. Kahn is professor and chair of the department of oral and maxillofacial pathology.

Boston University

George Huang, DDS, has been named the Herbert Schilder professor in endodontics and director of the postdoctoral program in endodontics at Henry M. Goldman School of Dental Medicine. Dr. Huang has extensive experience teaching in both clinical and didactic settings. Since beginning his academic career, Dr. Huang has held faculty positions at Boston University, the University of California (San Diego and Los Angeles), the University of Maryland, Kaohsiung Medical University, and most recently Columbia University, where he was associate professor and director of the division of endodontics. ■





ART OF DENTISTRY

ERIC K. CURTIS, DDS, MAGD, ELS

Dr. Curtis is past president of the American Association of Dental Editors. In 2006, he received the American Dental Association's Distinguished Editor Award.

FORGET IT

OF COURSE YOU WILL REMEMBER THAT THIS TIME YOU WANT TO GIVE Julie Larkin 3% mepivacaine without a vasoconstrictor, and that the gingival hyperplasia you noticed last week on Tom Elfman could be related to his nifedipine regimen. You have no problem recalling, either, that you need to be done tonight before 6:00 so you can get to the school play on time. At least you'd better remember.

From the first time we gazed into our mother's eyes to the continuing education course we took last week, our lives are defined by the demands of memory. Memory—our ability to draw wisdom from experience—shapes and influences every aspect of our lives. Memory creates identity and animates our surroundings. Memory builds meaning. Our shared memories become culture. “The very essence of civilization consists of purposefully building monuments so as to not forget,” wrote L. S. Vygotsky, a Soviet psychologist and the founder of cultural-historical psychology.

But we forget all the time.

Memory is not a documentary of the events we experience but an interpretation. Our memory for faces, facts, songs, events, pictures, smells, and skills seems both vast and mostly trustworthy. Yet research on memory affirms that we continually edit, distort, forget, and recast the past as we create meaningful stories about ourselves. We filter and shade memory, enhancing some remembrances and blocking out others. “Just wait until now becomes then,” Susan Sontag wrote slyly. “You'll see how happy we were.” Author Francois de la Rochefoucauld called attention to our inevitably selective memory more bluntly: “Everyone complains of his memory, and no one complains of his judgment.”

We hate that we forget. “I just had it on the tip of my tongue,” we say, apologizing in conversation. Forgetting is clumsy, frustrating, and frightening; it can ruin a date, an exam, or a career. But at the same time, forgetting is a crucial mental process. Ironically, we must forget in order to remember. Forgetting is clearly an important part of effective remembering. “If we remembered everything,” the philosopher William James noted, “we should, on most occasions, be as ill off as if we remembered nothing. It would take as long for us to recall a space of time as it took the original time to elapse and we should never get ahead in our thinking.”

The Russian psychologist Alexander Luria wrote about a man who remembered too much. The man could hold on to seemingly unlimited facts and mental pictures of people and places he had seen. He was deeply unhappy; his extraordinary memory for minute details of the past overwhelmed and interfered with his experience of the present.

So although our entire personal and professional lives are arranged around what we remember, or want to remember, I propose that we dedicate a modest slice of our energies to doing just the opposite. Forgetting is not always an embarrassment, an annoyance, or an indication of the onset of Alzheimer's. It can be extremely beneficial. There are some things that we ought to actually try to forget. As dentists, for example, we would be better off forgetting at least three things: dogma, anger, and insularity.

Forget dogma. There are standards of care in dentistry, and a lot of talk about formulating parameters and indicators. Certainly, we must agree on thresholds of what constitutes acceptable care. But dentistry is not a religion. There has to be room for thoughtful experimentation for progress to occur. And there is usually room in a given treatment plan for several approaches.

Forget anger. It's time to cool off. Anger must not distort our relationship with patients, who must not become enemies or fodder in third-party tugs-of-war. Nor should we allow anger to interfere with our relationship with colleagues, with whom camaraderie diminishes stress and improves communication and patient care. It's time to put away anger for that certain dental school professor—you know who I mean. And it's certainly time to shelve the anger for organized dentistry. This is a democracy, vibrant and messy, full of give-and-take. It will only improve if you make it improve. Which brings me to the next point:

Forget insularity. That's isolation. Dentists are the sovereigns of solitude. So get out. Get involved in the community. Sign on for a project. Don't just do the things you're paid for. Volunteer somewhere. Go to work on a committee at the dental association.

As you struggle to remember everything in your busy schedule, leave a little space in the day planner for a small shift in your point of view. Don't forget to forget. Your memory may not improve, but your memories will. ■

